

Rituximab as pre-emptive treatment in patients with thrombotic thrombocytopenic purpura and evidence of anti-ADAMTS13 autoantibodies

Elena Bresin¹; Sara Gastoldi¹; Erica Daina¹; Daniela Belotti²; Enrico Pogliani²; Paolo Perseghin³; Potito R. Scalzulli⁴; Rossella Paolini⁵; Raimondo Marcenò⁶; Giuseppe Remuzzi^{1,7}; Miriam Galbusera¹

¹Mario Negri Institute for Pharmacological Research, Clinical Research Center for Rare Diseases Aldo e Cele Daccò, Ranica, Bergamo, Italy; ²Units of Hematology, Immunohematology and Blood Transfusion Center, "San Gerardo" Hospital, Monza, Italy; ³Therapeutic Apheresis Unit, "San Gerardo" Hospital, Monza, Italy; ⁴Unit of Hematology, "Casa Sollievo della Sofferenza" Hospital, San Giovanni Rotondo, Italy; ⁵Unit of Oncology, Azienda Ospedaliera of Rovigo, Italy; ⁶Unit of Transfusion Medicine, "V. Cervello" Hospital, Palermo, Italy; ⁷Division of Nephrology and Dialysis, Azienda Ospedaliera, Ospedali Riuniti di Bergamo, Italy

Summary

Thrombotic thrombocytopenic purpura (TTP) is a rare and severe disease characterized by thrombocytopenia, microangiopathic haemolytic anemia, neurological and renal involvement associated with deficiency of the von Willebrand factor-cleaving protease, ADAMTS13. Persistence of high titers of anti-ADAMTS13 autoantibodies predisposes to relapsing TTP. Since relapses are associated with high morbidity and mortality rates, the optimal therapeutic option should be a pre-emptive treatment able to deplete anti-ADAMTS13 autoantibodies and avoid relapses. Five patients who presented with persistence of undetectable ADAMTS13 activity and high titers of autoantibodies, were treated with rituximab as pre-emptive therapy during remission. Four of them were affected by relapsing TTP and one was treated after the first episode. ADAMTS13 activity ranging

from 15% to 75% with disappearance of inhibitors was achieved after three months in all patients, and persisted >20% without inhibitors at six months. In three patients disease-free status is still ongoing after 29, 24 and six months, respectively. Relapses were documented in two patients during follow-up: in one patient remission lasted 51 months; while in the other patient relapse occurred after 13 months. Results demonstrated that rituximab used as pre-emptive treatment may be effective in maintaining a sustained remission in patients with anti-ADAMTS13 antibodies in whom other treatments failed to limit the production of inhibitors, and suggests that re-treatment with rituximab should be considered when ADAMTS13 activity decreases and inhibitors reappear into the circulation, to avoid a new relapse.

Keywords

TTP, rituximab, ADAMTS13, autoantibodies, rare diseases

Thromb Haemost 2009; 101: 233–238

Introduction

Thrombotic thrombocytopenic purpura (TTP) is a rare and severe disease characterized by thrombocytopenia, microangiopathic haemolytic anemia, neurological and renal involvement (1). The disease may manifest once during life or it may relapse after recovery. Relapses are still associated with high morbidity and mortality rates.

The presence of unusually large (UL) von Willebrand factor (VWF) multimers in the plasma of patients with recurrent TTP, described by Moake et al. (2), led to the implication of these multimers in the pathogenesis of the platelet-rich thrombi that

occlude arterioles. In healthy subjects ADAMTS13, a VWF-cleaving metalloprotease, prevents the entrance into the circulation of ULVWF multimers. Deficient or severely reduced ADAMTS13 activity would imply that UL multimers of VWF are not proteolyzed upon secretion and continue to circulate allowing platelet deposition into growing, potentially occlusive thrombi.

After the first two studies demonstrating that ADAMTS13 activity was severely reduced in patients with TTP (3, 4), this protease has been extensively evaluated in patients with thrombotic microangiopathies. A recent review of the literature reported that severe deficiency of the protease ADAMTS13 in dif-

Correspondence to:

Erica Daina, MD

Mario Negri Institute for Pharmacological Research
Clinical Research Center for Rare Diseases Aldo e Cele Daccò
24020 Ranica, Bergamo, Italy
Tel.: +39 035 4535304, Fax: +39 035 4535373
E-mail: edaina@marionegri.it

Received: December 27, 2007

Accepted after major revision: October 17, 2008

Prepublished online: January 15, 2009

doi:10.1160/TH07-12-0753

ferent cohorts of patients with TTP varies from 43% to 94% (5). In a small group of patients the deficiency is constitutive due to mutations in the corresponding ADAMTS13 gene, but in the majority of patients the deficiency is acquired due to the presence of circulating anti-ADAMTS13 autoantibodies. These autoantibodies may inhibit the protease (3, 4) or may induce the removal of the protease from the circulation (6, 7).

In comparison with patients without autoantibodies, patients with anti-ADAMTS13 inhibitors experience a more severe manifestation of the disease, need more plasma and have a higher mortality rates (8–11). There is evidence that patients with anti-ADAMTS13 autoantibodies have a high rate of relapses (9, 12, 13) and that undetectable ADAMTS13 and the persistence of anti-ADAMTS13 inhibitors during remission are predictors of recurrences (14).

To limit the production of autoantibodies in patients with relapsing TTP several therapies have been used including non selective immunosuppression with steroids, cyclophosphamide, vincristine, cyclosporine A, and azathioprine. The results reported for these treatments are highly variable and their use may predispose to frequent infectious complications (15).

Rituximab, a humanized monoclonal antibody directed against the B-cell antigen CD20 (16), induces a rapid depletion of B cells that usually lasts 6–9 months. Rituximab is used in the treatment of CD20-positive lymphoproliferative disorders, and recent studies suggest that this drug may be an effective treatment in various autoantibodies-mediated diseases including TTP (17–19).

Indeed, in the last few years rituximab has been successfully administered as additional treatment to patients with severe TTP refractory to standard therapy, and to date more than 70 patients have been treated with an high rate of response (reviewed in [18, 20, 21]). On the other hand, reports suggesting that rituximab may be useful as single pre-emptive therapy in patients with TTP associated with anti-ADAMTS13 autoantibodies are scant (22–26) and additional support to the evidence of therapeutical efficacy of rituximab in remission is needed.

In our case series we assessed whether rituximab, administered during remission in patients with relapsing TTP and persistence of high titers of anti-ADAMTS13 antibodies, could prevent recurrences and maintain a sustained disease-free state by

depleting the inhibitors and restoring a significant ADAMTS13 activity.

Patients, materials and methods

Patients were identified through the International Registry of Recurrent and Familial HUS/TTP, a network comprised actually of 154 Hematology and Nephrology Units from Italy and 11 European countries with the contribution of some extra-European centers, established in 1996 under the coordination of the Clinical Research Center for Rare Diseases *Aldo e Cele Daccò* (Ranica, Italy).

Adult patients (age >18 years) presenting with the following conditions were considered eligible for pre-emptive-rituximab: 1) at least one acute episode of TTP, defined by microangiopathic haemolytic anemia (haemoglobin <10 g/dl, lactate dehydrogenase [LDH] >460 IU/l, undetectable serum haptoglobin and the presence of schistocytes on blood smear) and thrombocytopenia (platelet count <150,000/ μ l), eventually associated with extra-haematologic symptoms; 2) current clinical remission, defined by normalization of standard blood parameters (platelet count >150,000/ μ l, haemoglobin >12 g/dl, LDH <460 IU/l) and absence of clinical manifestations of TTP for more than 30 days after the last plasma treatment; 3) undetectable ADAMTS13 activity (<6%) in plasma related to high titers of circulating anti-ADAMTS13 inhibitors.

Five Italian TTP patients with undetectable ADAMTS13 activity and high titers of anti-ADAMTS13 autoantibodies during remission were treated with rituximab, out of any clinical and hematological signs of disease: four presented the relapsing form, whereas one was treated after her first episode. The characteristics of the patients and the length of remission after pre-emptive-rituximab are summarized in Table 1.

Pre-emptive treatment with rituximab

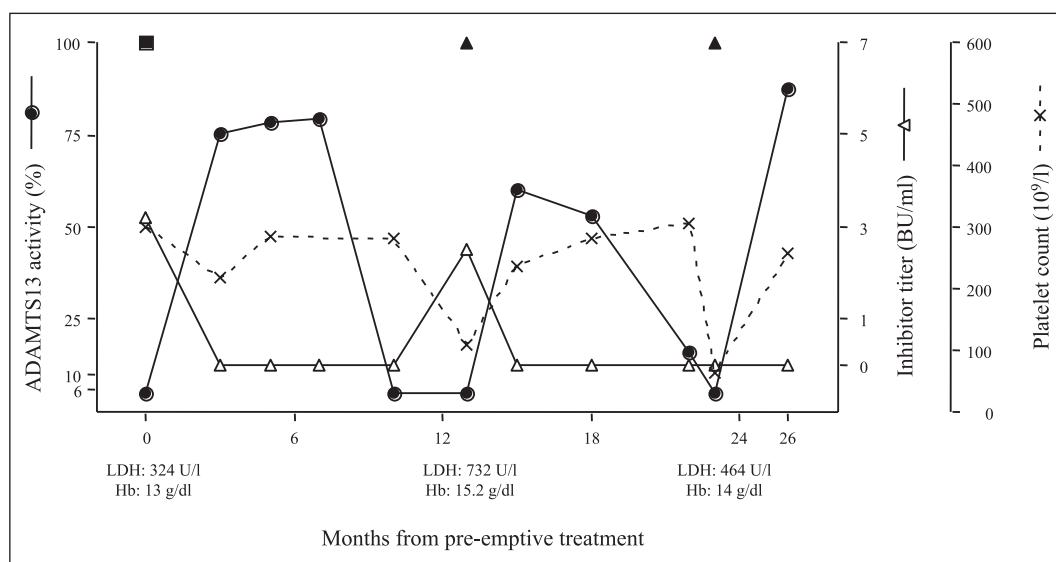
Patients received an infusion of rituximab at the dose of 375 mg/m² (Mabthera, Roche; Milan, Italy) weekly for four weeks with a premedication with methylprednisolone (30 mg intravenously), chlorphenamine (10 mg intravenously), acetaminophen (500 mg intravenously).

Case No.	Sex	Age at TTP onset (years)	Disease duration (years)	No. of TTP episodes	Neurologic/renal involvement	Previous treatment	Length of disease-free/follow-up* after pR (months)
1	M	48	10	>10	Yes/Yes	ASA, P, CS, IVIG, CPM, V, CSA, S	51
2	M	27	5	5	No/Yes	P, CS, ASA, IVIG, V, Vb, R	13
3	M	37	5	3	Yes/Yes	P, CS, IVIG	29*
4	F	32	17	10	No/Yes	P, CS, IVIG, AZA	24*
5	F	57	1	1	Yes/Yes	P, CS, V, ASA, D, CPM, CSA, R	6*

ASA, aspirin; AZA, azathioprine; CS, corticosteroids; CSA, ciclosporin A; CPM, cyclophosphamide; D, defibrotide; IVIG, intravenous Ig; P, plasma therapy (plasma exchanges, plasmapheresis, plasma infusions); R, rituximab; S, splenectomy; V, vincristine; Vb, vinblastine.

Table 1: Characteristics of TTP patients treated with rituximab as pre-emptive treatment (pR).

Figure 1: Clinical course and response to rituximab in case 2. Sequential measurements of ADAMTS13 activity levels (●), inhibitor titer (Δ) and platelet count (X) after the initiation of pre-emptive rituximab therapy (■) at the dose of 375 mg/m² weekly for 4 weeks. LDH indicates values of lactate dehydrogenase (normal range: 230–460 U/l). Hb indicates values of haemoglobin (normal values: 14–18 g/dl). (▲) Other rituximab treatments.



Follow-up

After pre-emptive treatment with rituximab, patients were subsequently seen at least every three months for clinical evaluation and standard laboratory exams. Plasmatic ADAMTS13 activity and testing for anti-ADAMTS13 inhibitors were evaluated at the Clinical Research Center for Rare Diseases of Ranica.

ADAMTS13 assays

ADAMTS13 activity was measured as described (27) using the residual collagen binding assay (CBA). The detection limit of the assay is 6%.

The inhibitor titer (BU/ml) was measured using a procedure based on the Bethesda method (28). Values >1 BU/ml were considered high titer of inhibitor.

Results

Case 1

The case of this patient, a male now 63 years old, has already been reported in part previously (22, 23). He received rituximab as pre-emptive treatment twice, 19 months apart. ADAMTS13 activity became undetectable 16 and 24 months after rituximab courses, respectively.

Overall the patient's clinical and haematological status remained stable for 51 months when a relapse of TTP with thrombocytopenia, haemolytic anemia and neurologic symptoms was recognized; remission was obtained after treatment with plasma exchanges, one infusion of rituximab and cyclosporine A.

Case 2

This patient, a 35-year-old man, manifested his first episode of TTP in May 2000 at the age of 27 years. No abnormalities in the coagulation system were found. Remission was achieved with plasma exchange, corticosteroids and aspirin. Patient was maintained with corticosteroids and antiplatelet agents for a year. Between December 2001 and November 2003, he experienced three relapses treated with plasma exchanges and infusions, cor-

ticosteroids and aspirin. At the last relapse, a severe deficiency of ADAMTS13 activity (<6%) due to high levels of ADAMTS13 inhibitor was detected for the first time. Since the patient did not respond well to the standard therapies, vincristine was added (then substituted by vinblastine), and rituximab was also started at the dose of 375 mg/m² once a week for four weeks, obtaining finally haematologic remission. Vinblastine was continued for a year. Three months after rituximab, ADAMTS13 activity recovered (33%), and inhibitors were slightly detectable. Three months later ADAMTS13 activity was 56% without inhibitors. In February 2005, protease activity was again undetectable due to the presence of high levels of ADAMTS13 inhibitors. Vinblastine was stopped and on April 2005 (day 0; Fig. 1), a pre-emptive course of rituximab was started followed by a fast recovery of ADAMTS13 activity (75% without inhibitors). Time course of ADAMTS13 activity and inhibitors after pre-emptive-rituximab is shown in Figure 1. At month 10, platelet count was normal and protease activity was undetectable, despite the absence of ADAMTS13 inhibitors. At month 13, haematuria associated with mild thrombocytopenia and increase of LDH was observed. A high titer of ADAMTS13 inhibitors was also detected. The patient received four infusions of rituximab, obtaining fast increase of platelet count, ADAMTS13 activity and disappearance of inhibitors (Fig. 1). Eleven months later, the patient presented with mild signs of disease and promptly recovered after a new course of rituximab. For one year now he has maintained under rituximab treatment with one dose of 375 mg/m² every three months showing good clinical condition without signs of disease and stable ADAMTS13 activity.

Case 3

This patient, a 43-year-old man, developed his first episode of TTP in February 2001 at the age of 37, a week after urinary tract infection (with urine culture positive for *Escherichia coli*) treated with ciprofloxacin. He presented with purpura on the lower extremities, acute renal failure and haematuria. Treatment with plasma exchange and steroids was started. After an initial

improvement, the patient worsened and developed atrial fibrillation, seizures, motor aphasia and right hemiparesis. Cerebral computed tomography (CT) was negative. Plasma exchange treatment was continued daily, and steroids were increased (160 mg/day); anti-epileptic therapy and intravenous immunoglobulins were also started. Clinical and haematologic remission was reached after 40 plasma exchange procedures, and the patient was discharged under therapy with prednisone. Subsequently, he experienced two relapses in March 2002 and April 2005 both associated with urinary tract infection and treated with plasma exchanges, steroids and antibiotic therapy. During the second relapse a severe deficiency of ADAMTS13 activity (<6%) due to high levels of ADAMTS13 inhibitor was first detected, and the defect was not corrected by the above treatments. In February 2006 during remission, a pre-emptive treatment with rituximab was started. At month 3, ADAMTS13 activity recovered (55%) and ADAMTS13 inhibitors disappeared remaining undetectable thereafter. At the last follow-up (month 29), the patient was still in clinical and haematological remission and ADAMTS13 activity was 65% without inhibitors.

Case 4

The patient, a 50-year-old woman, developed her first episode of TTP in August 1989, at the age of 32. She was free of central nervous system abnormalities. Neither abnormalities in the coagulation system nor antinuclear antibodies were found. She was treated with corticosteroids, and clinical status and laboratory values improved. During the subsequent six years, the patient experienced five relapses treated with steroids and plasma infusions. In March 1996, she was readmitted to the hospital because of extensive bruising, petechiae, weakness, headache and acute renal failure. Therapy with steroids and plasma infusions was instituted, but the patient did not show improvement; remission was obtained with nine plasma exchange procedures. After the seventh relapse in July 1996, the patient was kept under therapy with azathioprine 50 mg/day for several years. Nevertheless, the patient experienced other two relapses in 2001 and 2005, improving with corticosteroids and plasmapheresis. Severe deficiency of ADAMTS13 activity (<6%) due to high levels of ADAMTS13 inhibitors was first detected during remission in 2001. The defect was never corrected by any of the mentioned treatments. In June 2006 during remission, a pre-emptive treatment with rituximab was started. Azathioprine had been stopped three months before. Three months after rituximab, ADAMTS13 activity recovered (59%) and ADAMTS13 inhibitors disappeared remaining undetectable thereafter. At the last follow-up (month 24) the patient was in clinical and haematological remission and ADAMTS13 activity was 26% with a very weak presence of inhibitors.

Case 5

The patient, a 59-year-old woman, developed her first episode of TTP in October 2006, at the age of 57, presenting with melena, fever, epigastralgia and asthenia. ADAMTS13 activity was found undetectable (<6%) due to high levels of ADAMTS13 inhibitors. Treatment with plasmapheresis and corticosteroids was started. After an initial improvement, the neurologic and haematologic status worsened. The patient received also vincristine, aspirin, defibrotide, cyclophosphamide and cyclosporine A but without

reaching remission. Treatment with rituximab was then started at the dose of 375 mg/m² once a week for four weeks obtaining finally complete remission. Cyclosporine A was continued for a year. Two months after rituximab, ADAMTS13 activity recovered (62%) and inhibitors were undetectable. In October 2007, after reappearance of high levels of ADAMTS13 inhibitor associated with severe decrease of the protease activity (<6%), cyclosporine A was discontinued and a pre-emptive course of rituximab was started followed by a fast recovery of ADAMTS13 activity, which reached the value of 68% two weeks after the first dose of rituximab. At the last follow-up (month 6) ADAMTS13 activity was 76% without inhibitors.

Discussion

Patients with TTP due to anti-ADAMTS13 autoantibodies have a high rate of relapse (9, 12, 13), and in recurrent cases death and neurological sequelae are common outcomes. Plasma exchange is the therapy of choice, but the possibility to perform plasma exchange can be limited by the availability of adequate structure and may expose patients to the risk of infections and of potentially serious complications that are often associated to this procedure (29). The ideal treatment should be the one capable of retarding and even preventing relapses, which occur so frequently in these patients.

In patients with the recurrent form of the disease the presence of antibodies has been reported not only during the acute phase but also in 30–40% of patients during remission (9), and this may be considered a predisposing factor to relapses. Specific therapies targeted to prevent the uncontrolled production of these autoantibodies are not available. Several immunosuppressive therapies have been tried to limit the production of these autoantibodies, including non-selective immunosuppression, but the response to these treatments is variable and often inconclusive (15). Contrasting results have also been obtained with splenectomy (15, 22, 24, 30).

The anti-CD20 chimeric monoclonal antibody rituximab has been used successfully as additional treatment in patients with chronic TTP refractory to standard therapies (18–20, 31).

The first clinical study in which rituximab was used in relapsing TTP as prophylactic treatment was done in the patient described here as Case 1. The study (22) compared also the effectiveness of rituximab versus plasma exchange – the standard therapy for TTP – in removing circulating ADAMTS13 antibodies. It was found that plasma exchange alone had little, transient effect on ADAMTS13 inhibitors, thus suggesting that this approach was not the elective therapy for preventing relapses in these patients. By contrast, rituximab treatment was followed by a progressive disappearance of inhibitors with a subsequent increase of protease activity. The recovery of B cells was followed by a decline in ADAMTS13 activity and reappearance of inhibitor after 16 months. A second course of rituximab – as sole therapy – induced a promptly disappearance of inhibitors and recovery of ADAMTS13 activity.

In the present series, biological remission consisting in ADAMTS13 activity ranging from 15% to 75% together with no detectable inhibitors was achieved at the three-month follow-up in all evaluated patients, and persisted >20% without inhibitors

at the six-month follow-up. Since it is known that ADAMTS13 activity levels above 5% are sufficient to protect from disease recurrences (32), rituximab could be the effective treatment to prevent relapses.

Our patients, after pre-emptive treatment with rituximab, maintained a prolonged disease-free state that lasted 51 months in Case 1; in Case 2 the disease-free period lasted 13 months, and in the three other cases a good clinical condition without signs of disease is still ongoing after 29, 24 and six months respectively.

Since the effect of the drug lasted for a variable period in each patient, as reported also by Fakhouri et al. (23), time of rituximab pre-emptive treatment should be determined by monitoring ADAMTS13 activity and autoantibodies. Three-month intervals should be appropriate to promptly recognise a decrease in ADAMTS13 activity and/or the appearance of inhibitors.

Rituximab was effective as sole therapy to prevent a full relapse and to restore normal protease activity on two occasions as shown by the clinical course of Case 2, when thrombocytopenia and haematuria were observed in association with undetectable ADAMTS13 activity.

No adverse reactions to rituximab infusion were observed in our patients; the therapy was well tolerated and did not cause infectious complications. Even though good tolerance of rituximab treatment has been previously reported in TTP case series (23, 31), questions about the long-term safety of B-cell therapy remain to be clarified. Because of its high activity, rituximab has improved the outcome of patients with B-cell malignancies and has been used with increasing frequency in the treatment of autoimmune rheumatic diseases. Its safety profile in the oncology setting is well known, with mild-to-moderate infusion-related reactions being the most common adverse events reported. Clinical experience in large series of patients with active rheumatoid arthritis to date has confirmed this (33). However, significant post-infusion syndromes have been reported, including Stevens-Johnson syndrome (34), cardiogenic shock (35) and vasculitis

(36). Serum sickness-like reactions, characterized by fever, rash, myalgias, and arthralgias, have also been described following rituximab therapy (37). Physicians should be aware of these possible associations and, due to potentially serious side effects, this treatment should be reserved only for patients with ADAMTS13 deficiency due to ADAMTS13 autoantibodies.

The current schedule for rituximab treatment is a dose of 375 mg/m² weekly for four weeks; however, recent reports demonstrated that patients in acute phase might obtain remission even with a single or two doses of rituximab (38, 39). Evidence that a single dose may be effective has been obtained also in another antibody-mediated disease such as idiopathic membranous nephropathy (40). This observation implies that trials are needed to compare the efficacy of reduced number of infusions or doses.

Our case series supports and strengthens the evidence that pre-emptive rituximab treatment during remission may be effective in maintaining a disease-free state in patients with anti-ADAMTS13 antibodies in whom other treatments failed to limit the production of inhibitors, and suggests that retreatment with rituximab should be considered when ADAMTS13 activity became undetectable and/or ADAMTS13 inhibitors reappear into the circulation, to avoid a new relapse.

These promising data provide the rationale to design a prospective controlled study in a larger group of patients with chronic relapsing TTP and acquired ADAMTS13 deficiency to evaluate whether rituximab significantly decreases the frequency of TTP relapses and to establish which prescription time schedule and dose is able to obtain the clinically expected goal of preventing relapses in the long-term.

Acknowledgements

We thank Sara Gamba (Clinical Research Center for Rare Diseases Aldo e Cele Daccò, Ranica), Nicola Cascavilla ("Casa Sollievo della Sofferenza" Hospital, San Giovanni Rotondo), Gioacchino Greco and Renato Messiva ("V. Cervello" Hospital, Palermo) for their valuable help.

References

1. Remuzzi G, Ruggenenti P, Bertani T. Thrombotic microangiopathies. In: Renal pathology with clinical and functional correlations. Philadelphia. J.B. Lippincott Company; 1994: 1154–1184.
2. Moake JL, Rudy CK, Troll JH, et al. Unusually large plasma factorVIII: von Willebrand factor multimers in chronic relapsing thrombotic thrombocytopenic purpura. *N Engl J Med* 1982; 307: 1432–1435.
3. Furlan M, Robles R, Galbusera M, et al. von Willebrand factor-cleaving protease in thrombotic thrombocytopenic purpura and the hemolytic-uremic syndrome. *N Engl J Med* 1998; 339: 1578–1584.
4. Tsai HM, Lian ECY. Antibodies to von Willebrand factor-cleaving protease in acute thrombotic thrombocytopenic purpura. *N Engl J Med* 1998; 339: 1585–1594.
5. Mannucci PM, Peyvandi F. TTP and ADAMTS13: when testing is appropriate? *Hematology Am Soc Hematol Educ Program* 2007; 2007: 121–126.
6. Scheiflinger F, Knobl P, Trattner B, et al. Nonneutralizing IgM and IgG antibodies to von Willebrand factor-cleaving protease (ADAMTS-13) in a patient with thrombotic thrombocytopenic purpura. *Blood* 2003; 102: 3241–3243.
7. Rieger M, Mannucci PM, Kremer-Hovinga JA, et al. ADAMTS13 autoantibodies in patients with thrombotic microangiopathies and other immunomediated diseases. *Blood* 2005; 106: 1262–1267.
8. Mori Y, Wada H, Gabazza EC, et al. Predicting response to plasma exchange in patients with thrombotic thrombocytopenic purpura with measurement of vWF-cleaving protease. *Transfusion* 2002; 42: 572–580.
9. Zengh XL, Kaufman RM, Goodnough LT, Sadler JE. Effect of plasma exchange on plasma ADAMTS13 metalloprotease activity, inhibitor level, and clinical outcome in patients with idiopathic and nonidiopathic thrombotic thrombocytopenic purpura. *Blood* 2004; 103: 4043–4049.
10. Bohm M, Betz C, Miesbach W, et al. The course of ADAMTS-13 activity and inhibitor titre in the treatment of thrombotic thrombocytopenic purpura with plasma exchange and vincristine. *Br J Haematol* 2005; 129: 644–652.
11. Coppo P, Wolf M, Veyradier A, et al. Prognostic value of inhibitory anti-ADAMTS13 antibodies in adult-acquired thrombotic thrombocytopenic purpura. *Br J Haematol* 2006; 132: 66–74.
12. Veyradier A, Obert B, Houllier A, et al. Specific von Willebrand factor-cleaving protease in thrombotic microangiopathies: a study of 111 cases. *Blood* 2001; 98: 1765–1772.
13. Vesely SK, George JN, Lammle B, et al. ADAMTS13 activity in thrombotic thrombocytopenic purpura-hemolytic uremic syndrome: relation to presenting features and clinical outcome in a prospective cohort of 142 patients. *Blood* 2003; 102: 60–68.
14. Ferrari S, Scheiflinger F, Rieger M, et al. Prognostic values of anti-ADAMTS13 antibody features (Ig isotype, titer, and inhibitory effect) in a cohort of 35 adult French patients undergoing a first episode of thrombotic microangiopathy with undetectable ADAMTS13 activity. *Blood* 2007; 109: 2815–2822.
15. Yomtovian R, Niklinski W, Silver B, et al. Rituximab for chronic recurring thrombotic thrombocytopenic purpura: a case report and review of the literature. *Br J Haematol* 2004; 124: 787–795.
16. Johnson PW, Glennie MJ. Rituximab: mechanisms and applications. *Br J Cancer* 2001; 85: 1619–1623.
17. Edwards JC, Cambridge G. B-cell targeting in rheumatoid arthritis and other autoimmune diseases. *Nat Rev Immunol* 2006; 6: 394–403.

18. Franchini M, Veneri D, Lippi G, et al. The efficacy of rituximab in the treatment of inhibitor-associated hemostatic disorders. *Thromb Haemost* 2006; 96: 119–125.
19. Heide F, Lipka DB, von Auer C, et al. Addition of rituximab to standard therapy improves response rate and progression-free survival in relapsed or refractory thrombotic thrombocytopenic purpura and autoimmune haemolytic anaemia. *Thromb Haemost* 2007; 97: 228–233.
20. George JN, Woodson RD, Kiss JE, et al. Rituximab therapy for thrombotic thrombocytopenic purpura: a proposed study of the Transfusion Medicine/Hemostasis Clinical Trials network with a systematic review of Rituximab therapy for immune-mediated disorders. *J Clin Apher* 2006; 21: 49–56.
21. Garvey B. Rituximab in the treatment of autoimmune haematological disorders. *Br J Haematol* 2008; 141: 149–169.
22. Galbusera M, Bresin E, Noris M, et al. Rituximab prevents recurrence of thrombotic thrombocytopenic purpura: a case report. *Blood* 2005; 106: 925–928.
23. Fakhouri F, Vernant JP, Veyradier A, et al. Efficiency of curative and prophylactic treatment with rituximab in ADAMTS13-deficient thrombotic thrombocytopenic purpura: a study of 11 cases. *Blood* 2005; 106: 1932–1937.
24. Reddy PS, Deauna-Limayo D, Cook JD, et al. Rituximab in the treatment of relapsed thrombotic thrombocytopenic purpura. *Ann Hematol* 2005; 84: 232–235.
25. Benetatos L, Vassou A, Bourants KL. Effectiveness of rituximab as prophylaxis in thrombotic thrombocytopenic purpura. *Clin Lab Haem* 2006; 28: 288–289.
26. Schleinitz N, Ebbo M, Mazodier K, et al. Rituximab as preventive therapy of a clinical relapse in TTP with ADAMTS13 inhibitor. *Am J Hematol* 2007; 82: 417–418.
27. Remuzzi G, Galbusera M, Noris M, et al. von Willebrand factor cleaving protease (ADAMTS13) is deficient in recurrent and familial thrombotic thrombocytopenic purpura and haemolytic uremic syndrome. *Blood* 2002; 100: 778–785.
28. Lattuada A, Rossi E, Calzarossa C, et al. Mild to moderate reduction of a von Willebrand factor cleaving protease (ADAMTS-13) in pregnant women with HELLP microangiopathic syndrome. *Haematologica* 2003; 88: 1029–1034.
29. George JN. Thrombotic thrombocytopenic purpura. *N Engl J Med* 2006; 354: 1927–1935.
30. Kremer-Hovinga JA, Studt JD, Demarmels Biasutti F, et al. Splenectomy in relapsing and plasma-refractory acquired thrombotic thrombocytopenic purpura. *Haematologica* 2004; 89: 320–324.
31. Scully M, Cohen H, Cavenagh J, et al. Remission in acute refractory and relapsing thrombotic thrombocytopenic purpura following rituximab is associated with a reduction in IgG antibodies to ADAMTS-13. *Br J Haematol* 2007; 136: 451–461.
32. Barbot J, Costa E, Guerra M, et al. Ten years of prophylactic treatment with fresh frozen plasma in a child with chronic relapsing thrombotic thrombocytopenic purpura as a result of a congenital deficiency of von Willebrand factor-cleaving protease. *Br J Haematol* 2001; 113: 649–651.
33. Keystone E, Fleischmann R, Emery P, et al. Safety and efficacy of additional courses of rituximab in patients with active rheumatoid arthritis: an open-label extension analysis. *Arthritis Rheum* 2007; 56: 3896–3908.
34. Lowndes S, Darby A, Mead G, et al. Stevens–Johnson syndrome after treatment with rituximab. *Ann Oncol* 2002; 13: 1948–1950.
35. Millward PM, Bandarenko N, Chang PP, et al. Cardiogenic shock complicates successful treatment of refractory thrombotic thrombocytopenic purpura with rituximab. *Transfusion* 2005; 45: 1481–1486.
36. Kandula P, Kouides PA. Rituximab-induced leukocytoclastic vasculitis: a case report. *Arch Dermatol* 2006; 142: 246–247.
37. Todd DJ, Helfgott SM. Serum sickness following treatment with rituximab. *J Rheumatol* 2007; 34: 430–433.
38. Chemnitz J, Draube C, Scheid P, et al. Successful treatment of severe thrombotic thrombocytopenic purpura with the monoclonal antibody rituximab. *Am J Hematol* 2002; 71: 105–108.
39. Sallah S, Husain A, Wan JY, et al. Rituximab in patients with refractory thrombotic thrombocytopenic purpura. *J Thromb Haemost* 2004; 2: 834–836.
40. Cravedi P, Ruggenenti P, Sghirlanzoni MC, et al. Titrating rituximab to circulating B cells to optimize lymphocytolytic therapy in idiopathic membranous nephropathy. *Clin J Am Soc Nephrol* 2007; 2: 932–937.