© 2009 Schattauer GmbH, Stuttgart

Theme Issue Article

Pregnancy-associated thrombotic thrombocytopenic purpura

Jens Gerth[1]; Ekkehard Schleussner[2]; Karim Kentouche[3]; Martin Busch[1]; Mandy Seifert[1]; Gunter Wolf[1]

[1]Klinik für Innere Medizin III, Friedrich-Schiller-Universität, Jena, Germany; [2]Abteilung Geburtshilfe, Klinik für Frauenheilkunde und Geburtshilfe, Friedrich-Schiller-Universität, Jena, Germany; [3]Klinik für Kinder- und Jugendmedizin, Friedrich-Schiller-Universität, Jena, Germany

Summary

Thrombocytopenia during pregnancy is a common diagnostic and management problem. Several differential diagnosis must be considered including manifestations of thrombotic thrombocytopenic purpura (TTP). We report here on a case of a 21-year-old pregnant woman who presented initially severe thrombocytopenia (8 Gpt/l) in the 20th+1 week of gestation. The patient had an antibody against ADAMTS13, and enzyme activity was <5%. Immediate plasmapheresis treatment was initiated, followed by plasma infusions, and again plasmapheresis. A male neonate was delivered by caesarean section in the 32nd week of gestation. The child had an uncomplicated postnatal development. After delivery, the mother's platelet count and ADAMTS13 activity increased to normal values. This case shows interesting aspects of TTP in pregnancy and a close cooperation between obstetricians, nephrologists and pediatricians is necessary for a successful outcome of the pregnancy.

Keywords

Thrombotic thrombocytopenic purpura, pregnancy, ADAMTS 13, von Willebrand factor, plasmapheresis, thrombocytopenia

Thromb Haemost 2009; 101: 248–251

Introduction

Thrombocytopenia during pregnancy is not uncommon, and an asymptomatic reduction in platelets counts is found near term in about 5% of normal pregnancies (1–2). In contrast, the incidence of thrombotic thrombocytopenic purpura (TTP) is only one in 25,000 pregnancies (3). However, it is difficult to determine the exact incidence of TTP in pregnancy because several clinical features of TTP occur in women with preeclampsia (3). TTP during pregnancy can be either a *de novo* manifestation of disease or a recurrence of a previous known TTP triggered by the pregnant state. In an older series of TTP and haemolytic syndrome complicating pregnancy, a high maternal mortality and long-term morbidity has been reported (3). Nevertheless, data from the Oklahoma Registry showed that future pregnancy may be safe for women who have recovered from TTP (4). However, in older studies of microangiopathies in pregnancy not a clear distinction between TTP and the hemolytic uremic syndrome (HUS) was made (5).

Congenital and acquired deficiency of the "von Willebrand factor cleaving protease" (A Disintegrin And Metalloprotease, with ThromboSpondin-1-like domains; ADAMTS13) has been characterized as the hallmark in the pathophysiology of TTP in the past decade (6, 7). While in the rare familial forms, several mutations of the ADAMTS13 gene have been described, inhibitory antibodies against ADAMTS 13 can be detected in patients with an acquired TTP (8–10). Viral infections have been proposed as a trigger of anti-ADAMTS13 antibody production. In familial forms of TTP, pregnancy has been shown to be a risk factor for relapse of the disease. However, in another group of patients without congenital ADAMTS13 deficiency, TTP develops exclusively during pregnancy (11). In these women, specific proteins in the placental circulation have been proposed as inducing antigen-triggering antibody production against ADAMTS13. We describe a woman suffering from TTP in the second trimester due to anti-ADAMTS13 antibodies, who required intensive treatment to save the pregnancy.

Case report

A 21-year-old pregnant woman was transferred to our tertial perinatal care center for termination of the pregnancy due to the diagnosis of a severe HELLP (Haemolysis, Elevated Liver enzymes, Low Platelets) syndrome in the 20th+1 week of gestation (GA). Initial laboratory studies (Table 1) demonstrated severe haemolytic anemia, thrombocytopenia, and proteinuria. Apart from a two-week history of petechiae, dyspnoe, and general malaise the pregnancy had been uneventful until this time. In

Correspondence to:
Gunter Wolf, MD
Professor of Medicine
Department of Internal Medicine III
University Hospital Jena
Erlanger Allee 101, D-07740 Jena, Germany
Tel.: +49 3641 9324301, Fax: +49 3641 9324302
E-mail: gunter.wolf@med.uni-jena.de

Received: December 14, 2007
Accepted: May 2, 2008

Prepublished online: January 15, 2009
doi:10.1160/TH07-12-0739

Downloaded from www.thrombosis-online.com on 2012-05-25 | IP: 38.107.179.230
For personal or educational use only. No other uses without permission. All rights reserved.

early pregnancy, there were documented normal haemoglobin and platelet values. Past medical history revealed a spontaneous abortion in the 5th week of gestation 11 months before. There were no other illnesses in the past.

Upon clinical examination, skin and mucosa were pale, and on her forearms, knees and thighs multiple petechiae were seen. The patient had no edema, blood pressure was normal. Further clinical examination showed no abnormalities, in particular no signs of liver or central nervous system disease.

Obstetrical ultrasound revealed an appropriate for gestational age developed fetus without signs of structural anomaly, normal amniotic fluid and fetal echocardiography, but a zero flow in the umbilical artery, presumably due to the anemia-caused fetal hypoxia, and pathological uteroplacental perfusion as a sign of an abnormal placentation (Fig. 1).

Additional laboratory examinations revealed a negative Coombs test, normal levels of complement C3, C4 and CH 50, as well as undetectable antinuclear (ANA) and double stranded DNA-antibodies. An initial blood smear showed 8% schistocytes, and a working diagnosis of TTP was made.

The woman was advised in an interdisciplinary perinatological council and decided to prolongate the pregnancy. Prednisolone (1 mg/kg body weight) was started, and the patient received two units of packed red blood cells to keep the haematocrit level above 30% to normalize maternal-fetal oxygen supply. A low-dose heparin therapy with enoxaparin 40 mg subcutaneous (s.c.) daily was started to improve placental microcirculation. Immediate plasmapheresis therapy was initiated with substitution with fresh frozen plasma (50 ml/kg body weight). During the first treatment, the patient complained of whole body itching. On clinical examination, we found a generalized urticaria and periorbital edema. Therefore, albumin was used as substitute in the next treatment.

We subsequently received laboratory parameters showing that ADAMTS 13 activity was below 5% due to a specific antibody (confirmed on two further occasions). The activity of ADAMTS13 was determined by the collagen-binding method using recombinant, fully multimerized VWF preparation as the substrate for the protease (12). Autoantibodies against ADAMTS13 were measured by an inhibitor assay as previously described (13). We started again with fresh frozen plasma-substitution on the third plasmapheresis session and treated with 100 mg prednisone i.v. immediately before therapy. After these precautions, no further allergic reactions against fresh frozen plasma were observed. Plasmapheresis therapy was initially done daily and afterwards every other day for 10 treatment sessions. Haemolytic anemia responded very well with a continuous rise in haemoglobin levels and an immediate rise of platelet counts and, since all other haemolytic parameters had normalized, we discontinued plasma exchange on the 22nd+2 weeks of gestation but continued steroid therapy. During therapy the umbilical flow was normalized und fetal growth was within normal limits, while uteroplacental perfusion remained pathological. The patient was discharged with a close follow up of platelets and haemoglobin measurements and obstetric follow up examinations every two weeks.

On the 25th week GA, the patient was readmitted because of severe nose bleeding. Platelets were 31 Gpt/l and the haemoglobin level was 6.7 mM at this time. Four days before this second admission hemoglobin level and platelet counts were within normal limits, and no schistocytes were found during an ambulatory visit. Plasmapheresis therapy was restarted on a daily basis. Glucocorticoid dose was increased to 1 mg/kg body weight again. After an additional eight plasmapheresis treatments, platelets increased, and we switched our treatment strategy to a prophylactic fresh frozen plasma transfusion of 400 ml/week on an outpatient basis. The patient was discharged on 26th+3 weeks GA.

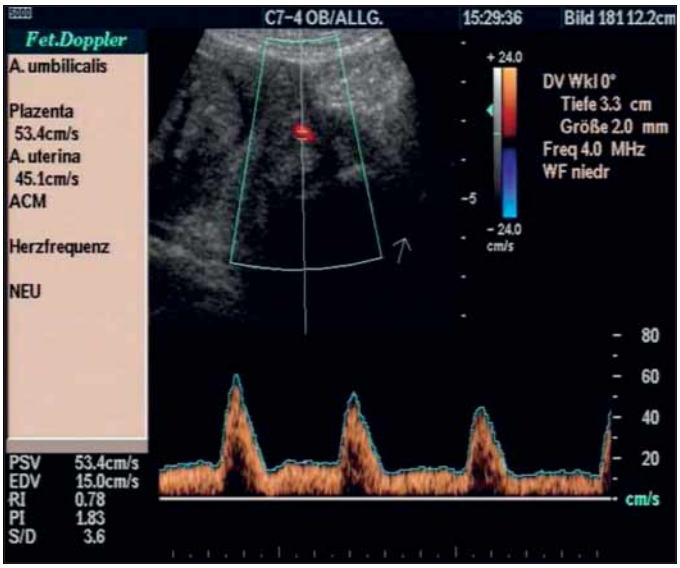

Figure 1: Pathological uteroplacental perfusion of the uterine arteria with a notch.

However, two weeks later the second relapse occurred with a continuous platelet decrease to 78 Gpt/l (haemoglobin 7.8 mM). Plasmapheresis therapy was restarted, and a total of nine consecutive daily treatment sessions were necessary to increase platelets and haemoglobin cocentration. Plasma exchange was then continued at three times per week. The fetal development was unaffected up to this time with normal fetal heart rate pattern and umbilical flow indices (estimated weight 1,110g < 50th percentile).

In the 30th week GA the patient developed a preeclampsia caused by the poor placentation with proteinuria reaching a protein excretion of 11 g/day. Antihypertensive therapy was started with methyldopa and hypertension was controlled in a range be-

Table 1: Laboratory data at admission.

Haemoglobin [mM]	4.3 [normal 7.6–9.5]
Haematocrit [%]	0.20 [normal 0.35–0.45]
Platelets[Gpt/l]	8 [normal 150–360]
Lactate dehydrogenase [µmol/sxl]	41.18 [normal <4.2]
Haptoglobin [g/l]	<0.06 [normal 0.3–2.0]
Creatinine [µM]	93 [normal 58–96]
Creatinine clearance [ml/min]	110 [normal 95–160]
Proteinuria [g/dl]	2.3 [normal <0.5 in pregnancy]

Downloaded from www.thrombosis-online.com on 2012-05-25 | IP: 38.107.179.230
For personal or educational use only. No other uses without permission. All rights reserved.

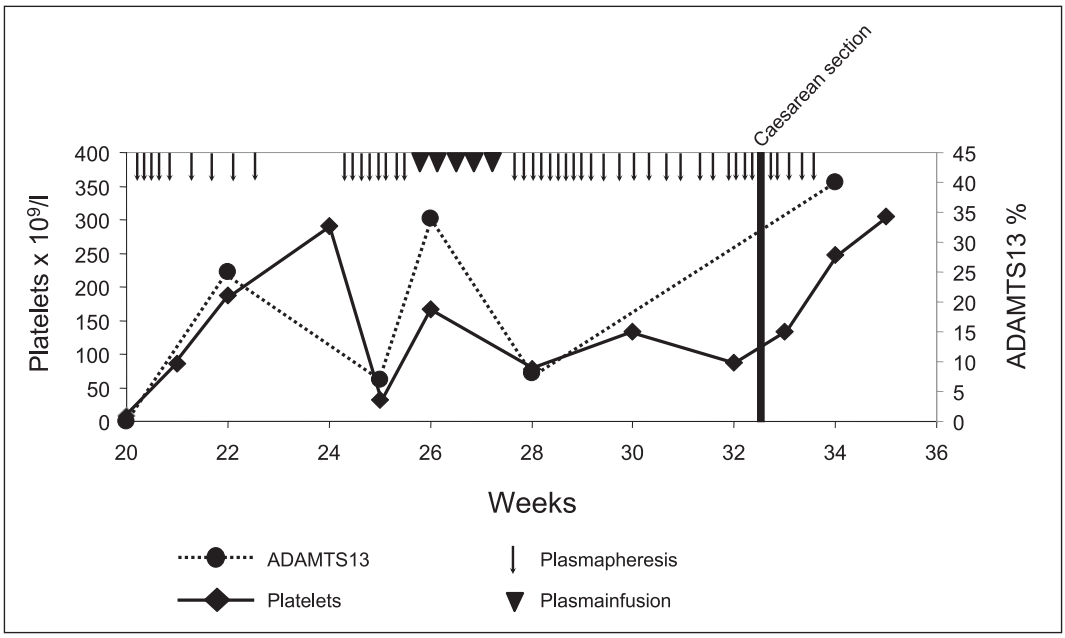

Figure 2: Platelet counts, ADAMTS13 activity and treatment sessions during the course of pregnancy.

tween 140–160/85–95 mmHg. Since symptoms of severe preeclampsia with hypertension, peripheral edema and proteinuria worsened further another perinatological council decided to finalize the pregnancy in the completed 32nd week GA. Therefore, the patient was treated with daily plasmapheresis for five consecutive days. Low-molecular-weight heparin was given until the day before and restarted four hours after caesarean section. The male neonate had a length of 42 cm and a weight of 1,729 g. The APGAR-score was 6/7/7 and the umbilical arterial pH was 7.29. There were no signs of neonatal thrombocytopenia. In fetal blood, ADAMTS13 activity was reduced to 15% and transmitted IgG-antibodies against ADAMTS13 were detectable. The child had an uncomplicated postnatal development and is growing well with no developmental deficits over now 40 months.

After delivery, six further plasmapheresis therapies were performed in the patient, but thereafter platelets remained in the physiologic range. Prednisolone was slowly tapered and completely stopped five months after delivery. Since heavy proteinuria was still present six weeks after delivery, ACE-inhibitor therapy was started (ramipril 2.5 mg twice/day). Proteinuria gradually decreased and ACE-inhibitor therapy was terminated after eight months when the proteinuria reached the physiologic range. An overview of the platelet counts and ADAMTS13 activity during the course of pregnancy is shown in Figure 2.

The patient became pregnant once again 12 months ago, but decided to terminate the pregnancy in the 9th week GA. At this time, platelets were reduced to 185 Gpt/l from 250 Gpt/l and schistocytes were present in the blood smear. After termination of the pregnancy, platelets quickly increased and have remained normal since then.

Discussion

TTP occurred in the second trimester of pregnancy with the typical features of haemolytic anemia, thrombocytopenia and petechiae but without kidney or central nervous system involvement in this case. Many of the reported cases of thrombotic microangiopathies are described preterm and postpartum, primarily due to a hypercoagulable state in the third trimester (14). A physiologic decrease in ADAMTS13 activity might also contribute to this hypercoagulable state in late pregnancy. Problems in the differential diagnosis to HELLP syndrome and severe preeclampsia contribute to the uncertainty regarding the typical time of onset of TTP in pregnancy (15, 16). Furthermore, case reports in the literature often do not distinguish between TTP and HUS (5, 17).

The mortality rate from thrombotic microangiopathies during pregnancy has significantly improved since plasmapheresis therapy has become the standard treatment (17). In a review of 45 cases of pregnancy-associated thrombotic microangiopathies between1966–1988, a maternal mortality of 44% and an associated fetal loss rate of 80% were described (18). Plasmapheresis has been particularly helpful in cases of TTP, because absent ADAMTS13 activity is replaced and antibodies against ADAMTS13 are removed. In pregnancy-associated TTP it is supposed that the pregnancy itself triggers thrombotic microangiopathy (19). Our patient, almost one year before this pregnancy, suffered a spontaneous abortion in the 5th week of pregnancy. Ten months after the successful delivery, she presented again in the 9th week of GA and thrombocytopenia was again detectable and she decided to terminate the pregnancy. This suggests a high relapse rate in pregnancy-triggered TTP-cases. This is in contrast to other reports, which suggest no higher risk for relapse of TTP in pregnancy (20). However, the pathophysiology of thrombotic microangiopathies was not clearly defined in these cases. Atypical HUS cases, congenital cases of TTP and antibody-mediated TTP cases are mixed together in these older reports. We did not look for ADAMTS13 mutations in our patient because we felt that this was a case of antibody-mediated TTP. Our patient never presented with episodes independent of the

Downloaded from www.thrombosis-online.com on 2012-05-25 | IP: 38.107.179.230
For personal or educational use only. No other uses without permission. All rights reserved.

pregnancies, and the pregnant state is known to induce potential development of autoantibodies (21).

Successful cases of pregnancy despite TTP have been previously described, and plasmapheresis as well as fresh-frozen plasma infusions have been recommended (3–5, 22, 23). However, only a few cases reported ADAMTS13 activity and the detection of autoantibody (4). In the presence of autoantibodies such as in our case, plasmapheresis is presumably superior to plasma infusion alone, similar to results obtained with TTP not associated with pregnancy (24).

Analyses of blood from the neonate showed a reduced ADAMTS13 activity to 15% as well as an anti-ADAMTS13 IgG-antibody. Platelet counts and haemoglobin levels were normal, and therefore a significant haemolysis was excluded. Since the molecular weight of IgG-antibodies allows them to cross the placental barrier, it is not surprising that the anti-ADAMTS13 antibody was found. Nevertheless, to the best of our knowledge transmission of anti-ADAMTS13 antibodies has not been previously described. We strongly believe that the intensive plasmapheresis therapy and fresh frozen plasma replacement were important factors in avoiding a significant haemolytic anemia in the fetal circulation, by reducing the anti-ADAMTS13 antibodies and by replacement of the ADAMTS13 enzyme in the maternal and fetal circulation.

In conclusion, only the close co-operation between obstetricians, nephrologists and pediatricians yielded the successful outcome of the pregnancy. Pregnancy is a risk factor for manifestation and relapse of anti-ADAMTS13 antibody-mediated TTP.

References

1. Parnas M, Sheiner E, Shoham-Vardi I, et al. Moderate to severe thrombocytopenia during pregnancy. Euro J Obstet Gynecol 2006; 128: 163–168.

2. Ajzenberg N, Dreyfus M, Kaplan C, et al. Pregnancy-associated thrombocytopenia revisited: assessment and follow-up of 50 cases. Blood 1998; 92: 4573–4580.

3. Egerman RS, Witlin AG, Friedman SA, et al. Thrombotic thrombocytopenic purpura and hemolytic uremic syndrome in pregnancy: review of 11 cases. Am J Obstet Gynecol 1996; 175: 950–956.

4. Vesely SK, Li X, McMinn JR, et al. Pregnancy outcomes after recovery from thrombotic thrombocytopenic purpura-hemolytic uremic syndrome. Transfusion 2004; 44: 1149–1158.

5. Yamanaka Y, Takeuchi K, Oomori S, et al. Two cases of clinically suspected thrombotic thrombocytopenic purpura/hemolytic uremic syndrome in the puerperium. Acta Obstet Gynecol Scand 2005; 84: 920–921.

6. McCrae KR, Cines DB. Thrombotic microangiopathy during pregnancy. Semin Hematol 1997; 34: 148–158.

7. Furlan M, Robles R, Galbusera M, et al. von Willebrand factor-cleaving protease in thrombotic thrombocytopenic purpura and the hemolytic-uremic syndrome. N Engl J Med 1998; 339: 1578–1584.

8. Tsai HM, Lian EC. Antibodies to von Willebrand factor-cleaving protease in acute thrombotic thrombocytopenic purpura. N Engl J Med 1998; 339: 1585–1594.

9. Levy GG, Nichols WC, Lian EC, et al. Mutations in a member of the ADAMTS gene family cause thrombotic thrombocytopenic purpura. Nature 2001; 413: 488–494.

10. Donadelli R, Banterla F, Galbusera M, et al. In-vitro and in-vivo consequences of mutations in the von Willebrand factor cleaving protease ADAMTS13 in thrombotic thrombocytopenic purpura. Thromb Haemost 2006; 96: 454–464.

11. George NG. The role of ADAMTS 13 in the pathogenesis of thrombotic thrombocytopenic purpura-hemolytic uremic syndrome. Clin Adv Hematol Oncol 2005; 3: 627–632.

12. Schneppenheim R, Budde U, Oyen F, et al. von Willebrand factor cleaving protease and ADAMTS13 mutations in childhood TTP. Blood 2003; 101: 1845–1850.

13. Kentouche K, Zintl F, Angerhaus D, et al. von Willebrand factor-cleaving protease (ADAMTS13) in the course of stem-cell transplantation. Sem Thromb Hemost 2006; 32: 98–104.

14. Franchini M. Haemostasis and pregnancy. Thromb Haemost 2006; 95: 401–413.

15. George N. The association of pregnancy with thrombotic thrombocytopenic purpura-hemolytic uremic syndrome. Curr Opin Hematol 2003; 10: 339–344

16. Mannucci PM, Canciani MT, Forza I, et al. Changes in health and disease of the metalloprotease that cleaves von Willebrand factor. Blood 2001; 98: 2730–2735.

17. Baeyer v H. Plasmapheresis in thrombotic microangiopathy-associated syndromes: Review of outcome data derived from clinical trials and open Studies. Ther Apher 2002; 6: 320–328.

18. Weiner CP. Thrombotic microangiopathy in pregnancy and the postpartum period. Semin Hematol 1987; 24: 119–129.

19. Proia A, Paesano R, Torcia F, et al. Thrombotic thrombocytopenic purpura and pregnancy: a case report and a review of the literature. Ann Hematol 2002; 81: 210–214.

20. Castellá M, Pujol M, Juliá A, et al. Thrombotic thrombocytopenic purpura and pregnancy: a review of ten cases. Vox Sang 2004; 87: 287–290.

21. Buyon JP. The effects of pregnancy on autoimmune diseases. J Leukoc Biol 1998; 63: 281–287.

22. Illter E, Haliloglu B, Temelli F, et al. Thrombotic thrombocytopenic purpura and pregnancy treated with fresh-frozen plasma infusions after plasmapheresis: a case report. Blood Coagul Fibrinolysis 2007; 18: 689–690.

23. Gunther K. Successful pregnancy despite thrombotic thrombocytopenic purpura in the first trimester. Transfusion 2006; 46: 1456–1457.

24. Rock GA, Shumak KH, Buskard NA, et al. Comparison of plasma exchange with plasma infusion in the treatment of thrombotic purpura. Canadian apheresis study group. N Engl J Med 1991; 325: 393–397.

Downloaded from www.thrombosis-online.com on 2012-05-25 | IP: 38.107.179.230
For personal or educational use only. No other uses without permission. All rights reserved.