

## Heyde's syndrome: From controversy to mainstream

Theodore E. Warkentin<sup>1</sup>; Jane C. Moore<sup>2</sup>

<sup>1</sup>Department of Pathology and Molecular Medicine, Michael G. DeGroot School of Medicine, McMaster University, Hamilton, Ontario, Canada; <sup>2</sup>Department of Medicine, Michael G. DeGroot School of Medicine, McMaster University, Hamilton, Ontario, Canada

Edward Heyde, an internist, remarked in correspondence to the *New England Journal of Medicine* in 1958 that he had seen "at least 10 patients with calcific aortic stenosis who had massive gastrointestinal bleeding for which [he] could discover no cause," hoping "that a letter to a prominent journal might elicit some response about the matter" (1). Eventually, the sites of aortic stenosis-associated gastrointestinal (GI) bleeding – submucosal vascular abnormalities termed "angiodyplasia" – were identified (2). But subsequent literature argued both for and against the existence of any link between aortic stenosis and bleeding GI angiodyplasia (for review see [3]). Perhaps this syndrome's darkest hour occurred when a negative study (4) prompted an editorialist (5) to declare: "Angiodyplasia and aortic valve disease: Let's close the book on this association."

But, one "rosetta stone" observation argued strongly for the existence of Heyde's syndrome: aortic valve replacement usually cured the GI bleeding! This amazing fact was illustrated dramatically in a study by King et al. (6), who reported 14 patients with Heyde's syndrome, all of whom had abrupt cessation of GI bleeding post-aortic

valve replacement, including 11 patients needing warfarin anticoagulation for their mechanical prosthesis. The historical rosetta stone, by providing an identical text in three languages (classical Greek, demotic and hieroglyphic Egyptian), yielded the crucial clues for decipherment of the hitherto obscure hieroglyphics. Similarly, we believed, solving the conundrum of surgical cure of bleeding GI angiodyplasia by aortic valve replacement promised to unravel the nature of this mysterious association.

In 1992, we hypothesised (7) that Heyde's syndrome could be explained by an acquired deficiency of the high-molecular-weight (HMW) multimers of von Willebrand factor (VWF), i.e. a subcategory of von Willebrand syndrome (VWS) type 2A. Among the key arguments supporting this explanation: (a) congenital and acquired aortic stenosis had recently been linked to deficiency of large VWF multimers (8, 9); (b) other causes of acquired VWS-2A (e.g. monoclonal gammopathy) were associated with bleeding GI angiodyplasia (10); (c) patients with congenital disorders characterised by defective primary haemostasis (e.g. von Willebrand disease, Bernard-Soulier-Syndrome) could develop intractable GI bleeding, usually beginning in middle age (11, 12). Further, (d) the high shear of aortic stenosis could contribute to VWF clearance through accelerated VWF-platelet interactions (13). Later, (e) another factor explaining shear-dependent loss of HMW multimers of VWF was found – namely, the shear-dependent VWF-cleaving metalloprotease, ADAMTS13 (14). Together, these observations suggested that VWS-2A could explain not only the pathophysiological basis for Heyde's syndrome, but crucially, its potential for surgical cure.

Gradually, data emerged that directly supported this hypothesis. We observed two patients with bleeding GI angiodyplasia who following aortic valve replacement had prompt cessation of bleeding, and

long-term recovery of their preoperative deficiency of HMW multimers, with no bleeding or VWS-2A recurrence at mean 10-year follow-up (15). Veyradier et al. in a case-control study found that most patients with bleeding GI angiodyplasia had acquired VWS-2A, whereas control subjects (including non-bleeding angiodyplasia patients) did not (16). Vincentelli et al. (17) reported that VWS-2A is commonly found in patients with severe aortic stenosis and that the laboratory abnormalities correlated with severity of valve stenosis. Furthermore, aortic valve replacement corrected or improved the VWF abnormalities, provided that the prosthetic valve was not too small for patient size (17).

In this issue of *Thrombosis and Haemostasis*, Panzer et al. (18) report their studies of impaired haemostasis in Heyde's syndrome and its post-surgical improvement. They studied 47 patients with severe aortic stenosis undergoing valve replacement. Some patients had easy bruising and recurrent epistaxis, although no patient was stated to have had bleeding GI angiodyplasia. This is not surprising; only a few patients with aortic stenosis have prominent GI bleeding, reflecting the requirement for concomitant GI angiodyplasia, and also perhaps a greater relative degree of haemostatic dysfunction. What did Panzer and colleagues find?

First, they confirmed that patients with aortic stenosis have reduced levels of HMW multimers of VWF that were increased significantly at six-month post-surgery follow-up. The median percent HMW multimers of VWF rose from approximately 18% to 26% (normal range in their study, 16% to 41%) post-valve replacement surgery ( $p < 0.0001$ ). These findings paralleled the correction of the adenosine diphosphate closure time (ADP-CT) in the PFA-100 instrument (Dade Behring, Marburg, Germany), a platelet function analyser used to measure the time needed for formation of a platelet plug after activation

### Correspondence to:

Dr. T. Warkentin  
Hamilton Regional Laboratory Medicine Program  
Room 1-180A, Hamilton Health Sciences  
(Hamilton General Site)  
237 Barton St. E., Hamilton, Ontario, L8L 2X2 Canada  
Tel.: +1 905 527 0271 (extension 46139),  
Fax: +1 905 577 1421  
E-mail: twarken@mcmaster.ca

### Financial support:

Some of the studies described in this editorial commentary were supported by the McGregor Clinic Fund Grant and by the Heart and Stroke Foundation of Ontario (Grant #NA4984 and Grant #T4404).

Received: November 17, 2009

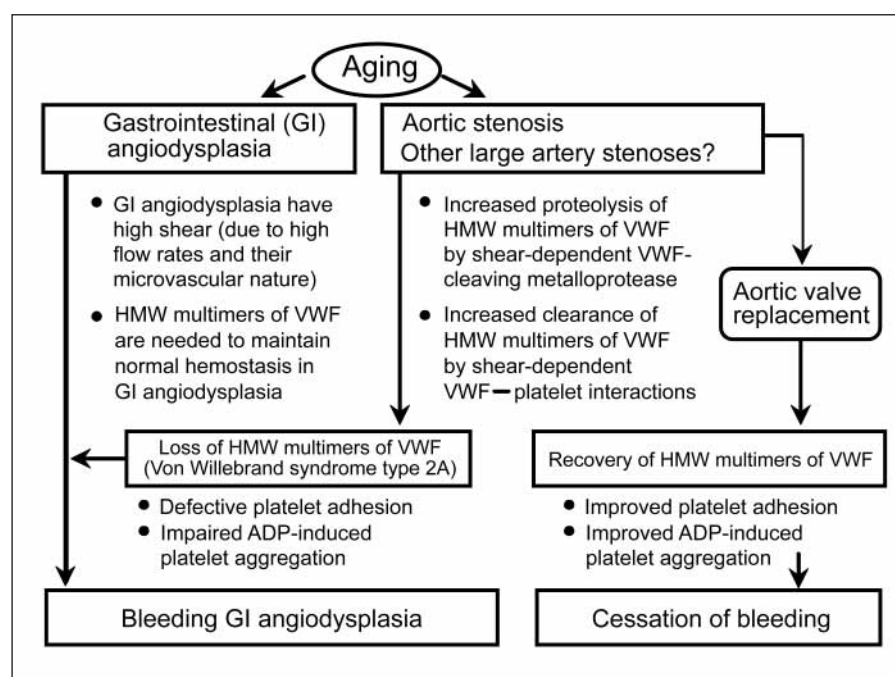
Accepted: November 17, 2009

Prepublished online: December 18, 2009

doi:10.1160/TH09-11-0779

Thromb Haemost 2010; 103: 251–253

Thrombosis and Haemostasis 103.2/2010



**Figure 1: Proposed pathogenesis of Heyde's syndrome and its cure by aortic valve replacement.** Modified, from reference 3, with permission.

of platelets *ex vivo* by collagen and ADP. Whereas 42 of 47 (89%) patients had a prolonged ADP-CT pre-surgery, only six (13%) patients had an abnormality post-valve replacement.

The authors also used a commercially-available cone and plate analyser, Impact-R (DiaMed, Cressier sur Morat, Switzerland), for the evaluation of platelet adhesion and aggregation using whole blood under high physiologic shear conditions ( $2,050\text{ s}^{-1}$ ), with and without added ADP. They found that the percent platelet surface coverage increased post-valve replacement, consistent with the important role of HMW multimers of VWF in mediating platelet adhesion under high shear. They also found that platelet aggregate size increased, but only when ADP was added to the whole blood prior to performing the cone and plate analyser studies. In parallel experiments, ADP-induced platelet P-selectin expression increased significantly post-valve replacement. Together, these observations indicate that aortic valve replacement leads to improvements both in platelet adhesion and also in platelet aggregation. It would have been interesting to perform these studies at even higher (pathophysiologic) shear rates ( $3,000$  to  $4,000\text{ s}^{-1}$ ), given that the presumed high shear rates in angiodysplasia help explain their striking predis-

position to bleed when HMW multimers of VWF are lacking.

► Figure 1 summarises a current view of Heyde's syndrome. Once mired in controversy, the link between aortic stenosis and bleeding GI angiodysplasia has entered the mainstream of biomedical research. These studies of Panzer et al. underscore the role of deficient HMW-VWF multimers in explaining this bleeding defect, and thus further deciphering the nature of this peculiar haemostatic defect, one that can be cured by the cardiac surgeon. As we have conjectured elsewhere (3), VWS-2A could be a common explanation for GI bleeding even in "vasculopathies" without aortic stenosis, as depletion of HMW multimers of VWF could also result from high shear within (non-valvular) vascular stenoses. No doubt with enhanced research focus we will continue to learn more about the pathophysiology of the bleeding defect in Heyde's syndrome.

## References

1. Heyde EC. Gastrointestinal bleeding in aortic stenosis. *N Engl J Med* 1958; 259: 196.
2. Greenstein RJ, McElhinney AJ, Reuben D, et al. Colonic vascular ectasias and aortic stenosis: coincidence or causal relationship? *Am J Surg* 1986; 151: 347–351.
3. Warkentin TE, Moore JC, Anand SS, et al. Gastrointestinal bleeding, angiodysplasia, cardiovascular disease, and acquired von Willebrand syndrome. *Transfus Med Rev* 2003; 17: 272–286.
4. Bhutani MS, Gupta SC, Markert RJ, et al. A prospective controlled evaluation of endoscopic detection of angiodysplasia and its association with aortic valve disease. *Gastrointest Endosc* 1995; 42: 398–402.
5. Gostout CJ. Angiodysplasia and aortic valve disease: Let's close the book on this association. *Gastrointest Endosc* 1995; 42: 491–493.
6. King RM, Pluth JR, Guilianeri ER. The association of unexplained gastrointestinal bleeding with calcific aortic stenosis. *Ann Thorac Surg* 1987; 44: 514–516.
7. Warkentin TE, Moore JC, Morgan DG. Aortic stenosis and bleeding gastrointestinal angiodysplasia: is acquired von Willebrand's disease the link? *Lancet* 1992; 340: 35–37.
8. Gill JC, Wilson AD, Endres-Brooks J, et al. Loss of the largest von Willebrand factor multimers from the plasma of patients with congenital cardiac defects. *Blood* 1986; 67: 758–761.
9. Salzman EJ, Weinstein MJ, Weintraub RM, et al. Treatment with desmopressin acetate to reduce blood loss after cardiac surgery. A double-blind randomized trial. *N Engl J Med* 1986; 314: 1402–1406.
10. Lambole V, Zabraniecki L, Sie P, et al. Myeloma and monoclonal gammopathy of uncertain significance associated with acquired von Willebrand's syndrome. Seven new cases with a literature review. *Joint Bone Spine* 2002; 69: 62–67.
11. Duray PH, Marcal JM Jr, LiVolsi VA, et al. Gastrointestinal angiodysplasia: A possible component of von Willebrand's disease. *Hum Pathol* 1984; 15: 539–544.
12. Okamura T, Kanaji T, Osaki K, et al. Gastrointestinal angiodysplasia in congenital platelet dysfunction. *Int J Hematol* 1996; 65: 79–84.

13. Chow TW, Hellums JD, Moake JL, et al. Shear stress-induced von Willebrand factor binding to platelet glycoprotein Ib initiates calcium influx associated with aggregation. *Blood* 1992; 80: 113–120.
  14. Tsai HM. Physiologic cleavage of von Willebrand factor by a plasma protease is dependent on its conformation and requires calcium ion. *Blood* 1996; 87: 4235–4244.
  15. Warkentin TE, Moore JC, Morgan DG. Gastrointestinal angiodysplasia and aortic stenosis. *N Engl J Med* 2002; 347: 858–859.
  16. Veyradier A, Balian A, Wolf M, et al. Abnormal von Willebrand factor in bleeding angiodysplasias of the digestive tract. *Gastroenterology* 2001; 120: 346–353.
  17. Vincentelli A, Susen S, Le Tourneau T, et al. Acquired von Willebrand syndrome in aortic stenosis. *N Engl J Med* 2003; 349: 343–349.
  18. Panzer S, Eslam RB, Schneller A, et al. Loss of high-molecular weight von Willebrand factor multimers mainly affects platelet aggregation in patients with aortic stenosis. *Thromb Haemost* 2010; 103: 408–414.
-