

What is your diagnosis? Answer

Cervical pain and paresis of left thoracic limb in a chondrodystrophic dog.

Discussion

On the left side of the myelogram (► Fig. 2), at the level of mid C6, a 'golf tee' sign could be seen, indicating an extramedullary, intradural mass lesion (1, 2). Combined with the clinical examination, the most probable diagnosis was an intradural tumour located on the left side of the spinal cord at C6.

Necropsy revealed a homogeneous mass over the normal spinal cord tissue, different in colour and in surface texture from the nerve tissue. This oval-shaped mass extended towards the left intervertebral foramina and the nerve root. Histopathology of the mass demonstrated the presence of tumour cells with moderate to high anaplasia, and numerous mitotic figures in some areas, together with evidence of invasion of the spinal cord (► Fig. 3). Based on these findings, a malignant nerve sheath tumour was diagnosed.

As it is impossible to determine the origin of these tumours, neoplasms growing within nerve sheath are in most cases classified into one of several categories of peripheral nerve sheath tumours. These categories include lesions derived from Schwann cells, perineural fibroblasts, and from other cells. This is reflected in the complex nomenclature of these

tumours, which are referred to as neurogenic sarcoma, malignant Schwannoma, malignant neurolemmoma, or neurofibrosarcoma (3). There are only few cases in the literature that described nerve sheath tumour in the West Highland White Terrier (4,5).

The key step in the diagnostic procedure leading to the diagnosis of a tumour located on the left side of the spinal cord, inside the dura at C6, was myelography. Splitting of the myelographic contrast column in the form of the 'golf tee' sign is characteristic of an intradural mass (2). One of the most common tumours of this type is the nerve sheath tumour (6). The reported case underscores the fact that, when making a differential diagnosis for neck pain, it is necessary to consider the possibility of soft or bone tissue tumour, or other differential diagnoses (6).

Diagnosis

Nerve sheath tumor in West Highland White Terrier

Acknowledgements

The authors would like to thank Professor Pierre Moissonnier, Professor Stephan Blot and Dr. Katarzyna Siewruk for the assistance provided at different stages of the diagnostic procedure.

References

1. Morgan JP, Bailey CS. Exercises in veterinary radiology, spinal disease. California: Venture Press 2000; 310–311.
2. Lorenz DM, Kornegay JM. Handbook of Veterinary Neurology, 4th ed. Philadelphia: Saunders 2004; 124–125.
3. MacEwen EG, Powers BE, Macy D, et al. Soft tissue sarcomas. In: Withrow SJ, MacEwen EG Small Animal Clinical Oncology. 3rd ed., Philadelphia: Saunders 2001; 283–304.
4. Brehm DM, Vite CH, Steinberg HS et al. A retrospective evaluation of 51 cases of peripheral nerve sheath tumors in the dog. *Vet Pathol* 1977; 14: 470–478.
5. Vasilopoulos RJ, Mackin AJ, Jennings D et al. What is your neurologic diagnosis? *J Am Vet Med Assoc.* 2002; 221:1397–1399.
6. Sharp NJH, Wheeler SJ Small animal spinal disorders, diagnosis and surgery. 2nd ed. Elsevier Mosby 2005; 50 – 54; 260 – 261.

Correspondence to

Dr. Beata Malgorzata Degórska
Warsaw University of Life Sciences
Faculty of Veterinary Medicine
ul. Nowoursynowska 159C
Warsaw 02–776, Poland
Phone: +48 22 847 3740
Fax: + 48 22 847 5898
E-mail: beata_degorska@sggw.p

Vet Comp Orthop Traumatol 2009; 22: 336

doi:10.3415/VCOT-08-10-0106

Received: October 28, 2008

Accepted: February 20, 2009

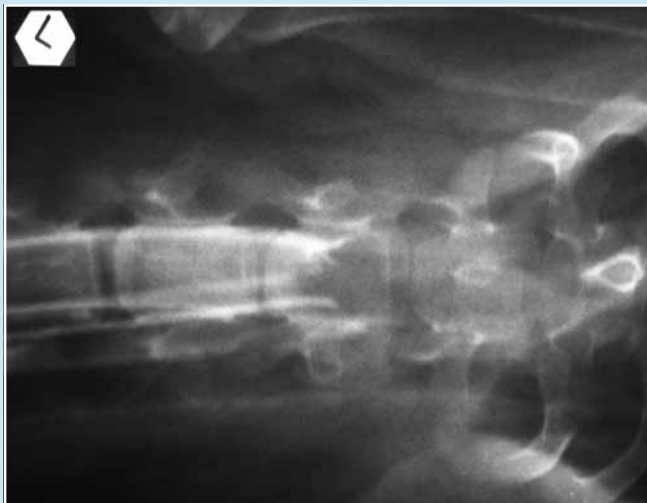

Fig. 2 Ventro-dorsal myelogram revealed pooling of the contrast agent at C6 with a 'golf tee' pattern on the left side of the spinal cord at C6.

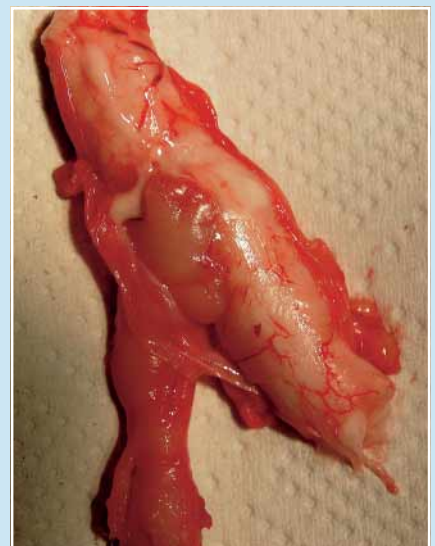


Fig. 3 Dorsal view of the pathology specimen. Note the oval mass compressing the left side of spinal cord, prolonged to the left root nerves.