

# Acute phase after haematopoietic stem cell transplantation

## Bleeding and thrombotic complications

L. Graf; M. Stern

Stem Cell Transplant Team and Division of Haematology, University Hospital Basel, Switzerland

### Keywords

Haematopoietic stem cell transplantation, diffuse alveolar haemorrhage, haemorrhagic cystitis, veno-occlusive disease, transplant-associated microangiopathy

### Summary

The transplantation of allogeneic or autologous haematopoietic stem cells is an established treatment for many malignant and non-malignant diseases of the bone marrow. Intensive cytoreductive regimens administered before transplantation induce prolonged and severe cytopenia of all haematopoietic lineages. Thrombocytopenia leads to an increased risk of bleeding, which may be further aggravated by consumption of plasmatic factors as a result of tumour lysis or after antibody administration. At the same time, patients after transplantation are also at increased risk of thrombotic complications. Endothelial damage induced by radio- and chemotherapy, indwelling catheters, prolonged immobilization and a high incidence of systemic infection all contribute to the frequent occurrence of thromboembolic events in this population.

This review discusses the incidence and risk factors for haemorrhagic and thrombotic complications after stem cell transplantation. Special emphasis is given to complications occurring specifically in the context of transplantation such as diffuse alveolar haemorrhage, haemorrhagic cystitis, veno-occlusive disease, and transplant associated microangiopathy.

### Schlüsselwörter

Stammzelltransplantation, diffuse alveoläre Hämorrhagie, hämorrhagische Zystitis, Venenverschlusskrankheit, transplantations-assoziierte Mikroangiopathie

### Zusammenfassung

Die Transplantation autologer oder allogener hämatopoietischer Stammzellen ist Routine in der Therapie maligner und nicht maligner Knochenmarkserkrankungen. Die zytoreduktive Therapie vor Transplantation induziert in aller Regel eine schwere und prolongierte Zytopenie aller drei Blutzellreihen. Die Thrombozytopenie führt dabei zu einem erhöhten Risiko von Blutungskomplikationen. Dieses Risiko kann zusätzlich verstärkt werden durch Veränderungen der plasmatischen Gerinnung als Folge einer Tumorlyse oder nach einer Antikörpertherapie. Patienten nach Transplantation erleiden auch häufig thrombotische Komplikationen. Chemo- und Radiotherapie-induzierte Endothelschäden, Venenkatheter, Immobilisation und häufige Infektionen tragen alle zu einem erhöhten Risiko von Thrombosen bei.

Diese Übersichtsarbeit diskutiert die Inzidenz und Risikofaktoren für Blutungs- und thrombotische Komplikationen nach Stammzelltransplantation. Dabei wird insbesondere auch auf Komplikationen eingegangen, welche spezifisch nach Transplantation auftreten, wie die diffuse alveoläre Hämorrhagie, die hämorrhagische Zystitis, die Venenverschluss-Krankheit, sowie die Transplantations-assoziierte Mikroangiopathie.

Haematopoietic stem cell transplantation (HSCT) is the transfer of multipotent haematopoietic stem cells. It is currently the only curative option for many malignant and non-malignant haematological diseases. Peripheral blood, bone marrow or umbilical cord are used as stem cell source.

- In autologous HSCT, the patient's own stem cells are returned to the body to resume haematopoiesis after myeloablative high-dose chemotherapy.
- In allogeneic HSCT, healthy donor stem cells from a family or unrelated volunteer donor are administered after myeloablative or non-myeloablative conditioning.

The allogeneic graft has the ability to initiate immune reactions through recognition of recipient antigens, which may lead to beneficial graft-versus-tumour effects and/or deleterious graft-versus-host disease (GvHD) (1, 2). Throughout the process of both autologous and allogeneic stem cell transplantation, haemostatic challenges can occur (3).

Growing evidence emerges that endothelial damage is a key contributing factor to both haemorrhagic and thrombotic complications through promotion of a procoagulant surface (3, 4).

Endothelial damage is the consequence of chemo- and radiotherapy administered before autologous and allogeneic HSCT (5), but occurs also due to graft-versus-host reactions in allogeneic HSCT (6). Other factors that can contribute to endothelial damages are treatment with growth factors (7) and indwelling catheters.

Data on alterations of procoagulant, anticoagulant and fibrinolytic factors in the early phase after HSCT are relatively sparse. It is reported that the levels of

### Correspondence to:

Martin Stern

Division of Haematology, University Hospital Basel  
Petersgraben 4, 4031 Basel, Switzerland  
Tel. +41/(0)61/328 73 90; Fax +41/(0)61/265 44 50  
E-mail: sternm@uhbs.ch

### Die akute Phase nach Stammzelltransplantation – Blutungen und thrombotische Komplikationen

Hämostaseologie 2012; 32: 56–62

doi:10.5482/ha-1176

received: September 18, 2011;

accepted: October 7, 2011;

prepublished online: October 18, 2011;

- natural anticoagulants protein C and antithrombin, the vitamin K-dependent factors V and X and plasminogen are reduced (8, 9),
- fibrinogen, von Willebrand factor, plasminogen activator inhibitor and tissue plasminogen activator are elevated (8, 10, 11).

In addition to the effects of the plasmatic coagulation, the myelosuppressive effect of the conditioning regimen leads to thrombocytopenia, which contributes to bleeding complications. All these changes in the coagulation system are responsible for an increased incidence of haemostatic complications in HSCT patients (3).

## Bleeding complications

Acute bleeding is associated with increased morbidity and mortality, and is a frequent complication after both allogeneic and autologous HSCT. Several studies have consistently shown that the risk of clinically relevant bleeding is at least 10-fold higher in a transplant population compared to general medical oncology patients undergoing chemotherapy (12–16). This section of the manuscript addresses incidence and risk factors of bleeding complications in the early phase after HSCT.

### Incidence

In the so far largest cohort study published by Gerber and co-workers (14), 230 of 1514 patients (15.4%) undergoing HSCT experienced clinically significant bleeding complications. This is comparable to other data (17, 18) even though “significant bleeding” is not defined uniformly. The majority of the bleeding events (39%) occurred in the gastrointestinal tract, followed by genitourinary (23%) and pulmonary bleedings (17%), and haemorrhage of the central nervous system (10%).

Given that 24% of these events were fatal, 3.6% of the HSCT patients in this cohort died from bleeding. Other authors reported comparable or slightly lower mortality rates from bleeding complications (15, 16).

### Risk factors

The strongest predictor of bleeding was the initiation of anticoagulation during the first half year following HSCT (OR 3.1). Other strong risk factors included the development of veno-occlusive disease (VOD; OR 2.2) and GvHD (OR 2.4) (14). In the study of Pihusch (15), two major peaks of bleeding incidences were identified:

- in patients without coexisting GvHD at around 10 days after HSCT during the thrombocyte nadir,
- around one month after HSCT in patients developing GvHD after engraftment.

In general, allogeneic HSCT recipients develop a more severe bleeding tendency than autologous HSCT recipients (RR 1.8) (14, 15). However, recent data suggest that the excess bleeding risk after allogeneic HSCT is restricted to patients developing GvHD, and that patients without GvHD are not at increased risk of bleeding after allogeneic HSCT (15, 19).

Almost all HSCT patients after myeloablative conditioning undergo an aplastic period with severe thrombocytopenia, which may become more severe and prolonged if acute GvHD occurs (20). Prolonged thrombocytopenia is an additional independent risk factor for bleeding episodes (15). A 1.5-fold (3.8% vs. 2.5%,  $p < 0.01$ ) and 3.8-fold (2.0 vs. 0.52%,  $p < 0.01$ ) risk of mild and severe bleeding, respectively, was observed in patients with a thrombocytopenic period of four months when compared with patients with a thrombocytopenic period of only one month. Furthermore, thrombocytopenia is a major risk factor for intracranial haemorrhage (21).

Anti-T-cell-globulin (ATG) is frequently given before transplantation as GvHD prophylaxis (22). Its use has been associated with an elevated risk of haemostatic disturbances and an increase in bleeding tendency (17, 23). The interaction of ATG with the haemostatic system are not well defined, but activation of the coagulation cascade as a consequence of cytokine release is supposed (23), which would explain the features of disseminated intra-

vascular coagulation frequently observed in patients following ATG administration.

## HSCT-specific haemorrhagic complications

### Diffuse alveolar haemorrhage

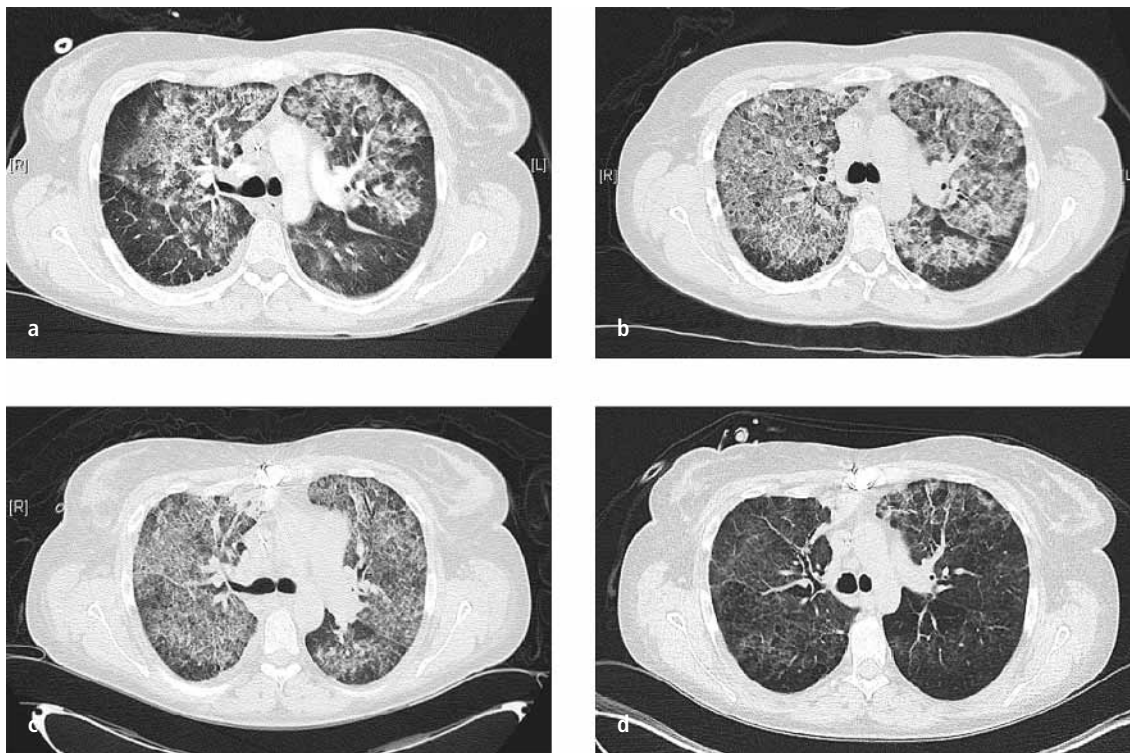
Diffuse alveolar hemorrhage (DAH) is a non-infectious pulmonary complication after HSCT with a poorly understood pathogenesis and a high mortality rate. In a prospective study by Majhail et al. (24), 45 of 1919 (2.3%) examined HSCT patients developed DAH, and 60-day survival from onset of haemorrhage was only 16%. Similar frequencies with a comparable incidence after autologous and allogeneic HSCT, but somewhat lower mortality rates are reported in other studies (25–27). In general, patients after autologous transplantation show a much better outcome after DAH develops (26). DAH is associated with (24)

- older age,
- allogeneic donor source,
- myeloablative conditioning regimen,
- acute GvHD.

However, a clear cause for the condition has not been identified so far. It is speculated that cytokine release following damage to alveolar capillary endothelium mediates the development of DAH.

Therefore, high-dose corticosteroid therapy is used considered first-line treatment (28), but dose and duration of steroid administration are not well defined. ► Figure 1 shows sequential pulmonary CT scans of a patient successfully treated with high dose steroids (1 g/day for 5 days) for DAH developing after allogeneic HSCT.

Despite the use of corticosteroids, mortality of DAH remains high, making the search for alternative or adjunct therapies necessary. The use of tranexamic acid in addition to corticosteroids showed promising results in a retrospective analysis (29) with a lower 100-day DAH mortality compared to patients treated with corticosteroids alone (44% vs. 83%), but until now this observation awaits confirmation in a prospective setting. Furthermore, in anecdotal reports, recombinant factor VIIa (rFVIIa) adminis-



**Fig. 1** Evolution of diffuse alveolar haemorrhage in sequential computed tomography scans. **a)** typical ground-glass infiltrates with sub-pleural sparing at diagnosis **b)** initial worsening of pulmonary function and radiological changes after 24 hours despite prompt initiation of high dose steroid treatment **c, d)** slow resolution one and two weeks after diagnosis and initiation of treatment

tered intravenously (30, 31) or intratracheally (32, 33) in DAH patients achieved temporary control of bleeding.

### Haemorrhagic cystitis

Haemorrhagic cystitis (HC) accompanied by microscopic or gross haematuria with clots that can lead to urinary tract obstruction occurs in 12–25% of HSCT patients (34, 35). HC is often associated with painful dysuria and resolves spontaneously in most cases. Nevertheless, HC has the potential to cause significant morbidity and mortality due to bladder tamponade causing renal failure (35).

- Early HC (day 1–3 after HSCT) is usually related to the toxic effects of the conditioning regimen, particularly the use of high dose cyclophosphamide.
- A second peak in HC – which is unrelated to conditioning regimen toxicity – occurs one to two months after HSCT (34, 36–39) and is associated with
  - allogeneic grafts,
  - advanced age,
  - GvHD,
  - thrombocytopenia,

- coagulopathy and
- viral infection (particularly polyoma BK virus, less frequently adenovirus and cytomegalovirus).

Treatment of HC is mainly supportive as the condition is self-limiting in most cases and neither antiviral therapy (34, 40) nor haemostatic therapy with rFVIIa (41) have proved to alleviate patients' symptoms successfully.

### Thrombotic complications

While less common and apparent than haemorrhage, thromboembolic complications also occur frequently in the early post-transplant period. Several treatment-related factors favour the development of both thromboembolic complications, as well as atypical thrombotic events such as veno-occlusive disease and transplant-associated microangiopathy: residual tumour load at the time of transplantation, prolonged immobilization, endothelial damage induced by the cytoreductive regimen or by graft-versus-host reactions, severe bacterial and fungal infections, and

the presence of indwelling central venous catheters all contribute to a pro-coagulant state (42). In addition, the majority of HSCT recipients do not receive thromboprophylaxis due to the profound thrombocytopenia induced by the conditioning regimen.

This part of the manuscript will summarize recent data on the incidence, pathogenesis and treatment of the most frequent thrombotic complications occurring after haematopoietic stem cell transplantation.

### VTE, catheter-related thrombosis

In the largest retrospective study so far incorporating more than 1500 transplant procedures, Gerber et al. defined incidence and risk factors for thrombotic complications after haematopoietic stem cell transplantation (14). All patients had indwelling catheters and none received pharmacological thromboprophylaxis. Two thirds of patients underwent autologous, the remaining allogeneic HSCT. By six months after transplantation, the incidence of symptomatic venous thromboembolism (VTE) amounted to 4.9%.

The majority of events were catheter-related VTEs (3.6%), whereas lower extremity DVT (0.7%) and pulmonary embolism (0.6%) occurred less frequently.

These incidences are in line with those found in smaller studies published previously (15, 43). Thromboembolic events occurred at a median interval from transplantation of 35 days and at a median platelet count of 75 G/l with one third of events occurring at platelet counts below 50 G/l. The rate of clinically relevant bleeding complications in this cohort was significantly higher, by comparison (15.2%).

### Risk factors for VTE

The main risk factors predisposing to VTE were history of prior VTE (odds ratio 2.9) and development of graft-versus-host disease (OR 2.4). Similarly, other studies have shown that patients after allogeneic transplantation have higher rates of VTE compared to those treated with autologous transplantation, and within the allogeneic population development of graft-versus-host disease is consistently associated with an increased risk of VTE (15, 44). As a possible explanation, a recent detailed serial analysis of patients undergoing transplantation revealed that the onset of GvHD correlated with increased thrombin generation (as measured by F1 and F2 fragments) and impaired fibrinolysis (detected by a decrease in PAI-1) (45).

Polymorphisms in coagulation proteins such as the factor V G1691A mutation (factor V Leiden) or the prothrombin G20210A mutation are well-established risk factors for VTE in the general population. Only small studies have so far analyzed the impact of these mutations in transplant recipients. While Pihusch et al. found no effect of mutations (including factor V Leiden and prothrombin G20210A) in a cohort of 89 patients Abdelkefi et al. described an average relative risk of 3.3 for carriers of the factor V Leiden or prothrombin G20210A mutation, or low anti-thrombin, protein C or protein S activity (46, 47). Events were too rare, however, to calculate individual relative risk ratios. There is still little reason to believe that

**Tab. 1**  
Diagnostic criteria for veno-occlusive disease

criteria	symptoms
Seattle	At least two factors must be present within 20 days after transplantation) (60). <ul style="list-style-type: none"> <li>● hyperbilirubinaemia (total serum bilirubin &gt;2 mg/dl)</li> <li>● hepatomegaly or upper right quadrant pain of liver origin</li> <li>● sudden weight gain (&gt;2% of baseline body weight)</li> </ul>
Baltimore	Hyperbilirubinaemia and two additional factors must be present within 100 days of transplantation) (61). <ul style="list-style-type: none"> <li>● hyperbilirubinemia (total serum bilirubin &gt;2 mg/dl)</li> <li>● hepatomegaly</li> <li>● right upper quadrant pain of liver origin</li> <li>● sudden weight gain (&gt;5% of baseline body weight)</li> </ul>

these polymorphisms should not operate in the same manner as amply described in non-transplant settings.

### Treatment and prevention of VTE

Whether thromboprophylaxis might reduce the incidence of catheter-associated VTE in transplant patients is unclear. One retrospective study suggested that a short course of nadroparin (for 6 to 10 days after catheter insertion) did not reduce the incidence of VTE, which occurred at a median of 22 days after catheter insertion (48). Longer courses of LMWH (low molecular weight heparin) prophylaxis have so far not been studied. A single arm trial with minidose warfarin (1 mg/d fixed dose if platelet count >50 G/l) produced a comparatively low rate of VTE (3 catheter-related and 1 deep vein thrombosis occurring during 292 courses of high-dose chemotherapy with autologous stem cell rescue) with an acceptable low bleeding rate (4 bleeding episodes) (49). No controlled studies have, however, evaluated thromboprophylaxis in this setting so far.

Treatment of established VTE after HSCT is as for thromboembolic events outside the HSCT setting. Caution must be given to the increased risk of bleeding due to mucositis and thrombocytopenia in the immediate post-transplant phase, which may require dose reduction of the anti-coagulants, intensive monitoring and potentially prolonged and intensive haemostatic support with platelet concentrates.

### Veno-occlusive disease

Veno-occlusive disease (VOD, also termed sinusoidal obstructive syndrome, SOS) is an infrequent but severe complication after stem cell transplantation. Pathogenetically, toxic injury of the sinusoidal endothelial cells and hepatocytes is believed to lead to cell edema causing micro-occlusions, which eventually cause progressive hepatic damage and multi-organ failure. The diagnosis of VOD is primarily clinical (►Tab. 1). As hepatic failure after HSCT can be caused by alternative processes such as graft-versus-host disease, diagnosis of VOD is frequently confirmed histologically after transdermal or transjugular liver puncture.

Histology typically shows microthromboses and fibrin deposition in hepatic central venules, hepatic congestion, and signs of portal hypertension in the absence of inflammatory infiltrates. Reversal of the blood flow in hepatic veins documented by duplex ultrasound analysis also supports the diagnosis. However, this requires an experienced examiner and is frequently only detectable in the final stages of the disease. Various plasmatic markers of coagulation and fibrinolysis have been investigated as markers of VOD. Thrombomodulin, P- and E-selectins, tissue factor pathway inhibitor (TFPI), soluble tissue factor, and plasminogen activator inhibitor (PAI-1) have all been shown to be up-regulated during VOD (50). An elevated PAI-1 level has also been advocated as a diagnostic and prognostic marker for VOD (51).

The frequency of VOD is in the range of 10% after allogeneic stem cell transplan-

**Tab. 2** Consensus criteria for the diagnosis of transplant-associated thrombotic microangiopathy

consensus (ref.)	All criteria must be present.
International Working Group (62)	<ul style="list-style-type: none"> <li>● increased percentage of schistocytes in peripheral blood smear (&gt;4%)</li> <li>● de novo, prolonged or progressive thrombocytopenia (&lt;50 G/l or &gt;50% decrease from previous counts)</li> <li>● sudden and persistent increase in lactate dehydrogenase</li> <li>● decrease in haemoglobin concentration or increased red blood cell requirements</li> <li>● decrease in serum haptoglobin concentration</li> </ul>
BMT CTN Toxicity Committee (57)	<ul style="list-style-type: none"> <li>● RBC fragmentation and <math>\geq 2</math> schistocytes per high-power field on peripheral smear</li> <li>● concurrent increased serum lactate dehydrogenase above institutional baseline</li> <li>● concurrent renal* and/or neurologic dysfunction without other explanations</li> <li>● negative direct and indirect Coombs test results</li> </ul>

\* Doubling of serum creatinine from baseline or 50% decrease in creatinine clearance from baseline.

tation employing myeloablative conditioning regimens (50). Risk factors for VOD development are

- pre-existing hepatic damage,
- previous high-dose chemotherapy,
- previous abdominal irradiation,
- donor-recipient HLA disparity, and
- female gender.

VOD is rare after autologous transplantation and after allogeneic HSCT with reduced intensity conditioning.

While mild VOD may resolve spontaneously, the prognosis of patients with advanced stages is grim. To date, there is no treatment with proven efficacy for VOD and therefore standard treatment of VOD is mainly supportive. Increasingly, defibrotide, a polydisperse mixture of single-stranded oligonucleotides with antithrombotic and fibrinolytic effects on the microvascular endothelium is used to treat VOD. Defibrotide binds to microvascular endothelium via adenosine receptors, modulates platelet activity by enhancing levels of endogenous prostaglandins and thrombomodulin, and promotes fibrinolysis via up-regulation of TFPI and tissue plasminogen activator (t-PA). In clinical phase II studies, defibrotide showed remission rates in patients with VOD in the range of 40% (52, 53). Importantly, responses occurred in the absence of severe hemorrhage or other toxicity. Large phase III trials are currently being conducted.

The encouraging results with defibrotide in the treatment of VOD have also spawned interest in its use as a prophylactic agent. Several studies have shown excellent results using prophylactic defibrotide without undue toxicity (54, 55). Unfortunately, none of the studies on defibrotide treatment contained a control arm. Therefore many questions regarding therapeutic efficacy, optimal dosing and dosing interval remain open at this point in time. Therapeutic strategies that have been found to be ineffective in the treatment or prevention of VOD include the administration of tPA, antithrombin and low-dose heparin (50). Ursodeoxycholic acid, a hydrophilic non-hepatotoxic bile acid is frequently administered in VOD prophylaxis despite conflicting results from randomized trials due to its excellent toxicity profile and its potential protective effect from liver GvHD. Another important strategy to prevent severe VOD is to incorporate risk stratification, which enables transplant physicians to offer patients at very high risk for VOD a reduced intensity conditioning or T-cell depletion of the graft.

### Transplant-associated thrombotic microangiopathy

Transplant-associated (thrombotic) microangiopathy (TA-TMA, or TAM) is another serious complication after transplantation. It occurs in 5–10% of patients

treated with allogeneic transplantation and has a high mortality rate in excess of 50%. It shares many clinical and laboratory features with thrombotic thrombocytopenic purpura (TTP), a condition caused by a marked reduction of the von Willebrand factor cleaving protease ADAMTS-13, which leads to the accumulation of macromolecules of von Willebrand factor causing thrombotic microangiopathy. Thrombocytopenia, presence of schistocytes, elevation of lactic dehydrogenase, bilirubin and reticulocytes as signs of hemolysis, kidney failure, and neurologic abnormalities may occur in both conditions.

In contrast to TTP, TAM is not caused by ADAMTS-13 deficiency and plasma exchange only rarely improves the condition. While many etiological aspects of TAM are still unresolved, the initiating event is believed to be endothelial cell injury which promotes thrombosis and fibrin deposition in the microcirculation resulting in microangiopathic hemolytic anemia and platelet consumption (56). Risk factors for the development of TAM (57) include

- fungal or viral infection,
- presence of GvHD,
- female sex,
- unrelated or HLA-mismatched donor grafts,
- the use of
  - calcineurin inhibitors such as cyclosporine and
  - mTOR inhibitors such as sirolimus.

TAM usually develops within the first 100 days after transplantation. In an effort to standardize the diagnosis of TAM, two sets of consensus criteria have recently been proposed (► Tab. 2). It remains to be seen which set of criteria will prove more useful in daily practice.

No standard treatment for TAM is known. While plasma exchange is not generally recommended in the treatment of TAM, anecdotal evidence suggests that it may benefit a subgroup of patients. The recent demonstration of antibodies e. g. against complement factor H in patients with TAM responsive to plasma exchange might pave the way for a more differentiated use of this treatment option in selected patients in the future (56). In line with this, single case reports and small case series de-

scribe patients with TAM responding to the B-cell depleting anti-CD20 antibody rituximab (58). As of now, modification of the immunosuppressive regimen is frequently proposed as the first treatment step: as inhibitors of both calcineurin and mTOR have been implicated in the development of TAM, immunosuppression is frequently switched to high-dose corticosteroids. Finally, results of trials with eculizumab – a monoclonal antibody against the complement protein C5 producing excellent results in atypical hemolytic uremic syndrome (59) – are eagerly awaited.

## References

- Copelan EA. Hematopoietic stem-cell transplantation. *N Engl J Med* 2006; 354: 1813–1826.
- Korbling M, Freireich EJ. Twenty-five years of peripheral blood stem cell transplantation. *Blood* 2011; 117: 6411–6416.
- Nadir Y, Brenner B. Hemorrhagic and thrombotic complications in bone marrow transplant recipients. *Thromb Res* 2007; 120 (Suppl 2): S92–S98.
- Carreras E, Diaz-Ricart M. The role of the endothelium in the short-term complications of hematopoietic SCT. *Bone Marrow Transplant* 2011; doi:10.1038/bmt.2011.65.
- Palomo M, Diaz-Ricart M, Carbo C et al. Endothelial dysfunction after hematopoietic stem cell transplantation: role of the conditioning regimen and the type of transplantation. *Biol Blood Marrow Transplant* 2010; 16: 985–993.
- Tichelli A, Gratwohl A. Vascular endothelium as 'novel' target of graft-versus-host disease. *Best Pract Res Clin Haematol* 2008; 21: 139–148.
- Nadir Y, Hoffman R, Brenner B. Drug-related thrombosis in hematologic malignancies. *Rev Clin Exp Hematol* 2004; 8: E4.
- Gordon B, Haire W, Kessinger A et al. High frequency of antithrombin 3 and protein C deficiency following autologous bone marrow transplantation for lymphoma. *Bone Marrow Transplant* 1991; 8: 497–502.
- Collins P, Roderick A, O'Brien D et al. Factor VIIa and other haemostatic variables following bone marrow transplantation. *Thromb Haemost* 1994; 72: 28–32.
- Collins PW, Gutteridge CN, O'Driscoll A et al. Von Willebrand factor as a marker of endothelial cell activation following BMT. *Bone Marrow Transplant* 1992; 10: 499–506.
- Salat C, Holler E, Reinhardt B et al. Parameters of the fibrinolytic system in patients undergoing BMT: elevation of PAI-1 in veno-occlusive disease. *Bone Marrow Transplant* 1994; 14: 747–750.
- Klerk CP, Smorenburg SM, Otten HM et al. The effect of low molecular weight heparin on survival in patients with advanced malignancy. *J Clin Oncol* 2005; 23: 2130–2135.
- Kakkar AK, Levine MN, Kadziola Z et al. Low molecular weight heparin, therapy with dalteparin, and survival in advanced cancer: the fragmin advanced malignancy outcome study (FAMOUS). *J Clin Oncol* 2004; 22: 1944–1948.
- Gerber DE, Segal JB, Levy MY et al. The incidence of and risk factors for venous thromboembolism (VTE) and bleeding among 1514 patients undergoing hematopoietic stem cell transplantation: implications for VTE prevention. *Blood* 2008; 112: 504–510.
- Pihusch R, Salat C, Schmidt E et al. Hemostatic complications in bone marrow transplantation: a retrospective analysis of 447 patients. *Transplantation* 2002; 74: 1303–1309.
- Holler E, Kolb HJ, Greinix H et al. Bleeding events and mortality in SCT patients: a retrospective study of hematopoietic SCT patients with organ dysfunctions due to severe sepsis or GVHD. *Bone Marrow Transplant* 2009; 43: 491–497.
- Pihusch M. Bleeding complications after hematopoietic stem cell transplantation. *Semin Hematol* 2004; 41 (1 Suppl 1): 93–100.
- Nevo S, Vogelsang GB. Acute bleeding complications in patients after bone marrow transplantation. *Curr Opin Hematol* 2001; 8: 319–325.
- Rysler C, Stoffel N, Buser A et al. Effect of beta-blockers, Ca<sup>2+</sup> antagonists, and benzodiazepines on bleeding incidence in patients with chemotherapy induced thrombocytopenia. *Platelets* 2010; 21: 77–83.
- Dominiotto A, Raiola AM, van Lint MT et al. Factors influencing haematological recovery after allogeneic haemopoietic stem cell transplants: graft-versus-host disease, donor type, cytomegalovirus infections and cell dose. *Br J Haematol* 2001; 112: 219–227.
- Najima Y, Ohashi K, Miyazawa M et al. Intracranial hemorrhage following allogeneic hematopoietic stem cell transplantation. *Am J Hematol* 2009; 84: 298–301.
- Socie G, Schmoor C, Bethge WA et al. Chronic graft-versus-host disease: long-term results from a randomized trial on graft-versus-host disease prophylaxis with or without anti-T-cell globulin ATG-Fresenius. *Blood* 2011; 117: 6375–6382.
- Pihusch R, Holler E, Muhlhuber D et al. The impact of antithymocyte globulin on short-term toxicity after allogeneic stem cell transplantation. *Bone Marrow Transplant* 2002; 30: 347–354.
- Majhail NS, Parks K, DeFor TE, Weisdorf DJ. Diffuse alveolar hemorrhage and infection-associated alveolar hemorrhage following hematopoietic stem cell transplantation: related and high-risk clinical syndromes. *Biol Blood Marrow Transplant* 2006; 12: 1038–1046.
- Lewis ID, DeFor T, Weisdorf DJ. Increasing incidence of diffuse alveolar hemorrhage following allogeneic bone marrow transplantation: cryptic etiology and uncertain therapy. *Bone Marrow Transplant* 2000; 26: 539–543.
- Afessa B, Tefferi A, Litzow MR, Peters SG. Outcome of diffuse alveolar hemorrhage in hematopoietic stem cell transplant recipients. *Am J Respir Crit Care Med* 2002; 166: 1364–1368.
- Afessa B, Abdulai RM, Kremers WK et al. Risk factors and outcome of pulmonary complications after autologous hematopoietic stem cell transplant (HSCT). *Chest* 2011; doi: 10.1378/chest.10–2889.
- Raptis A, Mavroudis D, Suffredini A et al. High-dose corticosteroid therapy for diffuse alveolar hemorrhage in allogeneic bone marrow stem cell transplant recipients. *Bone Marrow Transplant* 1999; 24: 879–883.
- Wanko SO, Broadwater G, Folz RJ, Chao NJ. Diffuse alveolar hemorrhage: retrospective review of clinical outcome in allogeneic transplant recipients treated with aminocaproic acid. *Biol Blood Marrow Transplant* 2006; 12: 949–953.
- Pastores SM, Papadopoulos E, Voigt L, Halpern NA. Diffuse alveolar hemorrhage after allogeneic hematopoietic stem-cell transplantation: treatment with recombinant factor VIIa. *Chest* 2003; 124: 2400–2403.
- Hicks K, Peng D, Gajewski JL. Treatment of diffuse alveolar hemorrhage after allogeneic bone marrow transplant with recombinant factor VIIa. *Bone Marrow Transplant* 2002; 30: 975–978.
- Estella A, Jareno A, Perez-Bello Fontaina L. Intrapulmonary administration of recombinant activated factor VII in diffuse alveolar haemorrhage: a report of two case stories. *Cases J* 2008; 1: 150.
- Heslet L, Nielsen JD, Levi M et al. Successful pulmonary administration of activated recombinant factor VII in diffuse alveolar hemorrhage. *Crit Care* 2006; 10: R177.
- Silva Lde P, Patah PA, Saliba RM et al. Hemorrhagic cystitis after allogeneic hematopoietic stem cell transplants is the complex result of BK virus infection, preparative regimen intensity and donor type. *Haematologica* 2010; 95: 1183–1190.
- Gorczyńska E, Turkiewicz D, Rybka K et al. Incidence, clinical outcome, and management of virus-induced hemorrhagic cystitis in children and adolescents after allogeneic hematopoietic cell transplantation. *Biol Blood Marrow Transplant* 2005; 11: 797–804.
- Bogdanovic G, Priftakis P, Giraud G et al. Association between a high BK virus load in urine samples of patients with graft-versus-host disease and development of hemorrhagic cystitis after hematopoietic stem cell transplantation. *J Clin Microbiol* 2004; 42: 5394–5396.
- Giraud G, Priftakis P, Bogdanovic G et al. BK-viruria and hemorrhagic cystitis are more frequent in allogeneic haematopoietic stem cell transplant patients receiving full conditioning and unrelated-HLA-mismatched grafts. *Bone Marrow Transplant* 2008; 41: 737–742.
- Leung AY, Yuen KY, Kwong YL. Polyoma BK virus and hemorrhagic cystitis in haematopoietic stem cell transplantation: a changing paradigm. *Bone Marrow Transplant* 2005; 36: 929–937.
- Dalianis T, Ljungman P. Full myeloablative conditioning and an unrelated HLA mismatched donor increase the risk for BK virus-positive hemorrhagic cystitis in allogeneic hematopoietic stem cell transplanted patients. *Anticancer Res* 2011; 31: 939–944.
- Cesaro S, Hirsch HH, Faraci M et al. Cidofovir for BK virus-associated hemorrhagic cystitis: a retrospective study. *Clin Infect Dis* 2009; 49: 233–240.
- Pihusch M, Bacigalupo A, Szer J et al. Recombinant activated factor VII in treatment of bleeding complications following hematopoietic stem cell transplantation. *J Thromb Haemost* 2005; 3: 1935–1944.
- Tsakiris DA, Tichelli A. Thrombotic complications after haematopoietic stem cell transplantation: early and late effects. *Best Pract Res Clin Haematol* 2009; 22: 137–145.
- Gonsalves A, Carrier M, Wells PS et al. Incidence of symptomatic venous thromboembolism following

- hematopoietic stem cell transplantation. *J Thromb Haemost* 2008; 6: 1468–1473.
44. Stoffel N, Rysler C, Buser A et al. Leukocyte count and risk of thrombosis in patients undergoing haematopoietic stem cell transplantation or intensive chemotherapy. *Thromb Haemost* 2010; 103: 1228–1232.
  45. Pinomaki A, Volin L, Joutsu-Korhonen L et al. Early thrombin generation and impaired fibrinolysis after SCT associate with acute GVHD. *Bone Marrow Transplant* 2010; 45: 730–737.
  46. Pihusch M, Lohse P, Reitberger J et al. Impact of thrombophilic gene mutations and graft-versus-host disease on thromboembolic complications after allogeneic hematopoietic stem-cell transplantation. *Transplantation* 2004; 78: 911–918.
  47. Abdelkefi A, Ben Romdhane N, Kriaa A et al. Prevalence of inherited prothrombotic abnormalities and central venous catheter-related thrombosis in haematopoietic stem cell transplants recipients. *Bone Marrow Transplant* 2005; 36: 885–889.
  48. Lagro SW, Verdonck LF, Borel Rinkes IH, Dekker AW. No effect of nadroparin prophylaxis in the prevention of central venous catheter (CVC)-associated thrombosis in bone marrow transplant recipients. *Bone Marrow Transplant* 2000; 26: 1103–1106.
  49. Magagnoli M, Masci G, Castagna L et al. Prophylaxis of central venous catheter-related thrombosis with minidose warfarin in patients treated with high-dose chemotherapy and peripheral-blood stem-cell transplantation: retrospective analysis of 228 cancer patients. *Am J Hematol* 2006; 81: 1–4.
  50. Ho VT, Revta C, Richardson PG. Hepatic veno-occlusive disease after hematopoietic stem cell transplantation. *Bone Marrow Transplant* 2008; 41: 229–237.
  51. Salat C, Holler E, Kolb HJ et al. Plasminogen activator inhibitor-1 confirms the diagnosis of hepatic veno-occlusive disease in patients with hyperbilirubinemia after bone marrow transplantation. *Blood* 1997; 89: 2184–2188.
  52. Richardson PG, Elias AD, Krishnan A et al. Treatment of severe veno-occlusive disease with defibrotide: compassionate use results in response without significant toxicity in a high-risk population. *Blood* 1998; 92: 737–744.
  53. Richardson PG, Murakami C, Jin Z et al. Multi-institutional use of defibrotide in 88 patients after stem cell transplantation with severe veno-occlusive disease and multisystem organ failure: response without significant toxicity in a high-risk population and factors predictive of outcome. *Blood* 2002; 100: 4337–4343.
  54. Chalandon Y, Roosnek E, Mermillod B et al. Prevention of veno-occlusive disease with defibrotide after allogeneic stem cell transplantation. *Biol Blood Marrow Transplant* 2004; 10: 347–354.
  55. Dignan F, Gujral D, Ethell M et al. Prophylactic defibrotide in allogeneic stem cell transplantation: minimal morbidity and zero mortality from veno-occlusive disease. *Bone Marrow Transplant* 2007; 40: 79–82.
  56. Laskin BL, Goebel J, Davies SM, Jodele S. Small vessels, big trouble in the kidneys and beyond: hematopoietic stem cell transplantation-associated thrombotic microangiopathy. *Blood* 2011; 118: 1452–1462.
  57. Ho VT, Cutler C, Carter S et al. Blood and marrow transplant clinical trials network toxicity committee consensus summary: thrombotic microangiopathy after hematopoietic stem cell transplantation. *Biol Blood Marrow Transplant* 2005; 11: 571–5715.
  58. Au WY, Ma ES, Lee TL et al. Successful treatment of thrombotic microangiopathy after haematopoietic stem cell transplantation with rituximab. *Br J Haematol* 2007; 137: 475–478.
  59. Nurnberger J, Philipp T, Witzke O et al. Eculizumab for atypical hemolytic-uremic syndrome. *N Engl J Med* 2009; 360: 542–544.
  60. McDonald GB, Sharma P, Matthews DE et al. Venocclusive disease of the liver after bone marrow transplantation: diagnosis, incidence, and predisposing factors. *Hepatology* 1984; 4: 116–122.
  61. Jones RJ, Lee KS, Beschornner WE et al. Venocclusive disease of the liver following bone marrow transplantation. *Transplantation* 1987; 44: 778–783.
  62. Ruutu T, Barosi G, Benjamin RJ et al. Diagnostic criteria for hematopoietic stem cell transplant-associated microangiopathy: results of a consensus process by an International Working Group. *Haematologica* 2007; 92: 95–100.