

# Diagnosis of heparin-induced delayed type hypersensitivity

M. Schindewolf<sup>1</sup>; R. J. Ludwig<sup>2</sup>; M. Wolter<sup>3</sup>; K. Hardt<sup>3</sup>; R. Kaufmann<sup>3</sup>; E. Lindhoff-Last<sup>1</sup>; W.-H. Boehncke<sup>3\*</sup>; B. Kahle<sup>2\*</sup>

<sup>1</sup>Department of Internal Medicine (Division of Angiology), Hospital of the Johann Wolfgang Goethe University, Frankfurt am Main, Germany; <sup>2</sup>Department of Dermatology, University of Lübeck, Germany;

<sup>3</sup>Department of Dermatology, Hospital of the Johann Wolfgang Goethe University, Frankfurt am Main, Germany

## Keywords

Heparin, type IV allergic reaction, heparin-induced thrombocytopenia type II, adverse event, allergy, delayed type hypersensitivity

## Summary

Heparin is commonly used for prevention and therapy of thromboembolic diseases. Recently, work from a prospective epidemiological investigation has indicated, that heparin-induced skin lesions may be more frequent, than expected. Commonly, delayed-type hypersensitivity reactions can be identified as the cause of heparin-induced skin lesions. Rarely, immediate type hypersensitivity responses or immune-mediated heparin-induced thrombocytopenia (HIT) are diagnosed. It is of clinical importance to differentiate between those, as patient management is fundamentally different. **Patients, methods:** We evaluated diagnostic procedures used to identify causes of heparin-induced skin lesions. Based on clinical presentation, histology and/or allergologic testing in 32 patients, heparin-induced delayed-type hypersensitivity (HIHS) was diagnosed. **Results:** Sensitivity of histology and s.c. provocation was high, amounting to 100% or 78% respectively. All other tests were unspecific or had a low sensitivity: Immediate readings of prick tests were false negative in 81%. Patch, prick and i.c. testing had a sensitivity ranging from 3.1–15.6%. **Conclusion:** Based on these results and despite the limitations of histology we recommend performing a skin biopsy rather than allergologic testing for diagnosis

of HIHS. Compared to allergologic testing, results from histology are sensitive, readily available and may allow a differentiation from other causes of heparin-induced skin lesions.

## Schlüsselwörter

Heparin, allergische Reaktion vom Typ IV, unerwünschte Arzneimittelwirkung, Histologie

## Zusammenfassung

**Hintergrund:** Heparine werden erfolgreich zur Prophylaxe und Therapie thromboembolischer Erkrankungen eingesetzt. Unerwünschte Arzneimittelwirkungen der Heparintherapie (z. B. Blutungen, Haarausfall, Heparin-induzierte Thrombozytopenie vom Typ 1 und 2) sind gut charakterisiert. Zur Inzidenz und zu den Ursachen Heparin-induzierter Hautveränderungen lagen bis vor kurzem keine prospektiven Daten vor. Zahlreiche Fallberichte ließen eine relativ hohe Inzidenz vermuten. In einer prospektiven Untersuchung wurde bei internistischen Patienten eine hohe Inzidenz Heparin-induzierter Hautveränderungen festgestellt. Als Ursache wurde in allen Fällen eine allergische Reaktion vom Typ IV diagnostiziert. **Ziel** dieser Untersuchung ist der Vergleich allergologischer und histologischer Methoden in der Diagnostik allergischer Reaktionen vom Typ IV auf Heparine. **Patienten, Methoden:** Insgesamt nahmen 32 Patienten mit Heparin-induzierten Hautveränderungen an der Untersuchung teil. Bei ihnen wurde die Ursache der Hautveränderungen sowohl mittels Epikutan-, Prick- und Intrakutan- und Subkutan-Testung als auch mittels

Histologie untersucht. Zuvor war bei allen Patienten serologisch und funktionell eine Heparin-induzierte Thrombopenie (HIT) vom Typ 2 ausgeschlossen worden. **Ergebnisse:** Bei allen Patienten wurde als Ursache eine allergische Reaktion vom Typ IV diagnostiziert. Sensitivität der subkutanen Provokationstestung (78%) und der histologischen Untersuchung einer läsionalen Hautbiopsie (100%) waren hoch. Alle anderen diagnostischen Maßnahmen stellten sich entweder als unspezifisch heraus und/oder wiesen eine niedrige Sensitivität auf. Die Sofortablesung im Prick-Test zur Diagnose einer Typ-I-Sensibilisierung zeigte in 81% der Fälle ein falsch positives Ergebnis. Die Spätablesung von Epikutan-, Prick- und Intrakutantests zeigten eine Sensitivität zwischen 3,1% und 15,6%. **Schlussfolgerung:** Aufgrund dieser Ergebnisse empfehlen wir die histologische Untersuchung einer Hautprobe anstelle einer allergologischen Testung bei Patienten mit Heparin-induzierten Hautveränderungen. Im Vergleich zur allergologischen Testung, die in der Regel erst sechs Wochen nach Abheilung der Läsionen und erst nach Ausschluss einer HIT vom Typ 2 durchgeführt werden kann, sind histologische Ergebnisse kurzfristig verfügbar. Zusätzlich erlaubt die histologische Untersuchung den Ausschluss anderer Ursachen Heparin-induzierter Hautveränderungen.

## Correspondence to:

Ralf J. Ludwig, MD  
Department of Dermatology; University of Lübeck,  
Ratzeburger Allee 160, 23538 Lübeck, Germany  
Tel. +49/(0)451/500-254; Fax +49/(0)451/500-2981  
E-mail: ralf.ludwig@uk-sh.de

## Diagnostik Heparin-induzierter Hautveränderungen

Phlebologie 2010; 39: 226–231

Received: June 7, 2010

accepted in revised form: June 18, 2010

\* equal contributors

Heparin has been used as an anticoagulant for more than 60 years (1, 21). Well known side effects of heparin therapy are bleeding, osteoporosis, hair-loss, immune heparin-induced thrombocytopenia type 2 (HIT) and HIT type 1. Recently, heparin-induced skin lesions have been increasingly reported (3, 4, 11, 18). The clinical presentation of heparin-induced skin lesions varies, depending on at least five, so far described different causes:

- In an estimated over 95%, heparin-induced skin lesions are caused by a delayed-type hypersensitivity response (15, 19). We here propose the term heparin-induced hypersensitivity (HIHS) for this entity.
- So far, approximately 20–30 patients with heparin-induced skin lesions caused by immun-mediated HIT have been published (11). As immune HIT is a life-threatening condition, and initially has a clinical presentation similar to HIHS, recognition of heparin-induced skin lesions caused by HIT is crucial for the care of patients (23).
- Up to now, only few cases have been reported for type I allergic reactions to heparin, which clinically may differentially present ranging from local urticaria (22) to anaphylactic shock (3).
- One patient with low molecular weight heparin-induced necrosis, with unclear etiology, (20) and
- one patient with low molecular weight heparin-induced pustulosis (9) were recently published.

As neither data on the incidence of heparin-induced skin lesions, nor the respective causes are currently available, we initiated an epidemiologic investigation to determine the incidence of heparin-induced skin lesions. This investigation has revealed a high incidence of heparin-induced skin lesions, and HIHS was identified as the underlying cause in all patients (15). During this investigation we noted, that in patients with diagnosed HIHS based on clinical presentation and histology, diagnosis was only rarely confirmed by patch, prick and i. c. allergologic testing. We therefore systematically analyzed the sensitivity of the available diagnostic procedures for HIHS.

## Study design

### Patients

Patient recruitment procedures have been described in detail elsewhere (15). In brief, patients receiving s. c. anticoagulants (unfractionated heparin – UFH, low molecular weight heparin – LMWH, heparinoids and fondaparinux) were examined by one or more physicians participating in the study for the presence of anticoagulant-induced skin lesions. Previously, we focused on heparin-induced skin lesions in medical patients. Currently, additional patient cohorts as well as patients with fondaparinux-induced skin lesions are characterized for the presence of anticoagulant-induced skin lesions.

### Study procedures

A clinical examination was performed of the anticoagulant injection sites, as well as a full-body examination of the skin. If a heparin-induced skin lesion was suspected, a second investigator examined the patient. If required, further diagnostic procedures were performed, including a skin biopsy for haematoxylin–eosin staining, platelet count monitoring, heparin-induced platelet activation test (HIPA) and an enzyme-linked immunosorbent assay (ELISA) to detect anti-platelet-factor 4/heparin antibodies (6). If heparin-induced thrombocytopenia was excluded, patients with skin lesions underwent allergy testing (prick,

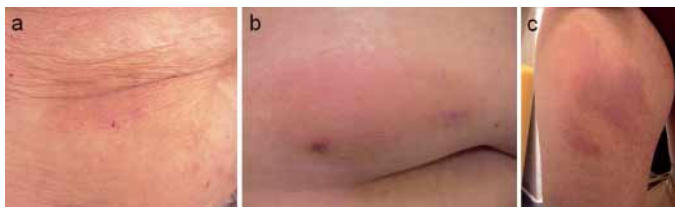
epicutaneous, intradermal and subcutaneous provocation) (11). Any investigations that needed to be repeated to confirm the diagnosis were performed 1–3 weeks later. Overall, 32 patients have been included here. These patients include patients reported in the prospective investigation on the incidence of heparin-induced skin lesions in medical patients (15). Sensitivity and specificity of diagnostic procedures to diagnose heparin-induced skin lesions was not in the focus of this previous study. Investigation and procedures were approved by the local ethics committee of the Johann Wolfgang Goethe University (16/07) and were registered at ClinicalTrials.gov (NCT00510432). All enrolled subjects gave their written informed consent to study participation.

### Skin biopsies

Skin biopsies from suspected heparin-induced lesions were obtained in local anesthesia and routinely processed for H&E staining. Samples were obtained when a heparin-induced skin lesion was observed. Median time from initiation of anticoagulant therapy to biopsy was 21 days (range 3–58 days). Biopsies were taken from the most recently developed lesions and stained with H&E. Sections were evaluated by two experienced dermatopathologists (MW and RK). Upon initiation of this investigation, presence of spongiosis, infiltration with leukocytes (eosinophils and lymphocytes in particular) were consider-

**Tab. 1** Diagnostic criteria to distinguish between HIT and HIHS established prior to the initiation of the study. As shown spongiosis has been excluded as an histological criteria, as it was not observed in all specimen.

	HIT	HIHS
history	-	itching
localization	at injection site, may rarely be distant (3)	initially at injection site, generalization relatively common (5)
clinical presentation	initial erythema, followed by necrosis	initial erythema, never necrosis, papules and scaling common
histology	microthrombi in dermal vessels (3)	mononuclear infiltrate (spongiosis)
platelet count	decrease	no change
anti-PF4 antibodies	yes	no



**Fig. 1** Representative clinical presentations of patients recruited in this study: A wide variation in the clinical presentation of HIHS was observed. The majority of patients presented with localized erythemas or plaques at the heparin injection sites (a, b). In a minority of patients, we also observed infiltrated plaques, development of small papulo-vesicles and/or scaling. However, in several patients HIHS generalization, originating from the injection sites was observed (c).

ed as DTH reaction. Based on published data on skin lesions in patients with HIT (2), occlusion of dermal vessels was defined as HIT-induced skin lesion.

### Allergologic testing

Testing (prick, patch, i. c. and subcutaneous provocation) was initiated no earlier than six weeks after clearance of suspected DTH lesions using undiluted original drug formulations as described elsewhere (12). More specifically, for skin allergy tests, UFH (Calciparin<sup>®</sup>, Sanofi-Aventis, Bad-Soden, Germany), LMWHs (nadroparin (Fraxiparin<sup>®</sup>), dalteparin (Fragmin<sup>®</sup>), tinzaparin (Innohep<sup>®</sup>), enoxaparin (Clexane<sup>®</sup>), certoparin (Mono-Embolex<sup>®</sup>) – from GlaxoSmithKline; Pfizer, Karlsruhe, Germany; Leo Pharma, Neu-Isenburg, Germany; Sanofi-Aventis; Novartis, Nürnberg, Germany; respectively), the heparinoid danaparonid (Organon, Paris, France) and synthetic pentasaccharid fondaparinux (Arixtra<sup>®</sup>, GlaxoSmithKline), were used.

For s. c. provocation the recommended single dose for the prophylactic indication was used. Test sites were monitored for de-

velopment of urticaria twenty minutes after exposure, and for eczematous reactions 24, 48 and 96 hours after exposure.

### Diagnostic criteria

Based on the history, clinical presentation, histology and or allergologic testing, the final diagnosis of heparin-induced skin lesions was made. The criteria used to distinguish between HIT and HIHS are listed in ►Table 1.

## Results

### Patient characteristics

We identified 35 eligible patients presenting with HIHS (►Fig. 1). Three were excluded, as neither histology, nor allergologic testing had been performed, which in all cases was due to lack of consent from patients. In total, data from 32 patients with HIHS diagnosed based on clinical presentation, histology and/or allergologic testing was available for analysis. Clinical presentation of HIHS ranged from local to generalized lesions. In most cases (n = 28) reac-

tions were restricted to the injection sites of heparin. In three cases lesions spread from the original injection sites, and one patient suffered generalization. Lesions developed nine days (mean, range: 1–52 days) after the initiation of s. c. anticoagulant treatment.

In this patient population, diagnosis of HIHS was based on histology and allergology testing in 18 patients, on allergology testing in 9 patients, and on histology in 5 patients. Mean age was  $50.0 \pm 15.3$  years, and patients were predominantly women. Based on the history, 27 patients had developed HIHS to a single heparin preparation, whereas three patients had reacted to two, and two other patients to three heparin preparations (►Tab. 2).

### High sensitivity of histology and provocation testing for the diagnosis of HIHS

With the exception of one patient, suffering from both immune HIT and HIHS, HIT was excluded in the patients by appropriate laboratory testing and histology. Skin biopsies were obtained from 23 patients, including the patient with concomitant HIT.

In all histological specimens, including the patient with concomitant HIT, a delayed-type hypersensitivity response was diagnosed, amounting to a 100% sensitivity of histology (►Tab. 3, ►Fig. 2). Regarding specificity, no conclusions can be drawn, as we did not include biopsies from unaffected skin and/or healthy control samples. In H&E stained sections, we frequently observed a lymphocyte infiltration in the dermis, which was predominantly located around the vasculature. By immunohistochemistry, most of the lymphocytes stained positive for CD3 and CD4 (not shown). In contrast, allergologic testing was either unspecific (immediate prick readings) or, with the exception of s.c. provocation, had a low sensitivity. More specifically, none of our patients had a history of an immediate-type reaction to heparin, but most patients showed wheals 20 minutes after prick testing with most heparin preparations.

Therefore, those responses have to be considered non-specific. Patch and prick

pattern of cross-reactivity		observed x-times
nadroparin,	enoxaparin, tinzaparin	1
	enoxaparin, danaparonid	1
	danaparonid	1
enoxaparin,	tinzaparin	1
	danaparonid	1

**Tab. 2**  
Cross-reactivities

testing with readings after 24, 48 and 96 hours each showed one right positive reading, amounting to a sensitivity of 3.3% and 3.1%, respectively. I. c. testing with readings after 24, 48 and 96 hours has a slightly better, but still low sensitivity of 15.6%. In contrast, s. c. provocation, which was only performed in patients who had not reacted in patch, prick and i. c. testing, has a comparable high sensitivity of 77.8% (▶ Tab. 3).

### Low cross-reactivity among heparin preparations

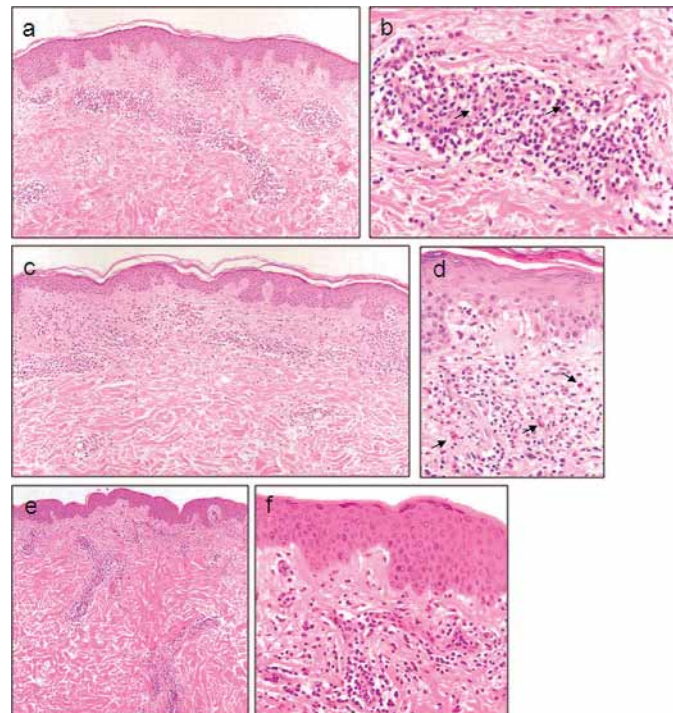
Allergy testing did not reveal any additional cross-reactivities in addition to the ones noted clinically. Overall cross-reactivity in our patient population is 15.6% (▶ Tab. 2). This is in contrast to earlier reports from several groups, including ours (8, 11, 14). Conversely, our population most likely differs from those previously reported (8, 11, 14): We here actively recruited patients with heparin-induced skin lesions, whereas previous patient populations consisted of patients referred to specialized allergy units.

## Discussion

Our prospective evaluation regarding the sensitivity of diagnostic procedures for patients with HIHS clearly showed, that both histology and s. c. provocation have high sensitivity. In contrast all other allergologic testing procedures are either unspecific, e. g. high number of false positive reactions in immediate reading of prick testing, or are of low sensitivity, such as patch, prick and intradermal testing. Upon initiation of the study to investigate the incidence and causes of heparin-induced skin lesions, using such diagnostic procedures to differentiate between the different causes, we expected a high sensitivity of allergologic testing, as reported before (8, 11, 14). We also expected to observe substantial cross-reactivity among the different heparins in the context of the skin tests; this would have been in line with previous studies reporting a high cross-reactivity in patients with HIHS (8, 11, 14). We hypothesize that this

striking difference in cross-reactivity is due to the difference in the earlier cohorts compared to the patients described here: previous reports focused on patients presenting to allergology departments for testing of suspected DTH reactions to heparin. Most likely, those patients had a long course of previous treatments, including prolong-

ed exposure to a variety of heparin preparations (16). In contrast we here have actively recruited patients with first onset DTH reactions to heparin and shorter exposition duration to the anticoagulant. We believe that, the development of cross-reactivity may depend on a longer exposition to heparin.



**Fig. 2** Representative histological specimen (a, c, e: 100-fold; b, d, f: 400-fold; H&E stained) from representative patients with HIHS: In all specimen investigated, a predominant dermal lymphocyte infiltration was observed. The infiltrate was most commonly located around vessels. Furthermore, a varying degree of eosinophil infiltration (→) was detected. In contrast to the severe inflammatory response changes in the epidermis (e. g. spongiosis) were rarely detectable. a, b) patient 1; c, d) patient 2; e, f) patient 3

**Tab. 3** Sensitivity of diagnostic procedures for HIHS: In all patients with heparin-induced skin lesions recruited for NCT00510432 study, HIHS was identified as the underlying cause (5). Numbers in table correspond to the actual number and the percentage of positive/negative results at the indicated tests (n/a: not applicable).

diagnostic procedure	false		right	
	negative	positive	negative	positive
histology	0/23 (0%)	0/23 (0%)	n/a	23/23 (100%)
immediate response	0/32 (0%)	26/32 (81%)	6/32 (19%)	n/a
Patch testing	29/30 (97%)	0/30 (0%)	n/a	1/30 (3%)
Prick testing	31/32 (97%)	0/32 (0%)	n/a	1/32 (1%)
i.c. testing	27/32 (84%)	0/32 (0%)	n/a	5/32 (16%)
s.c. provocation	6/27 (22%)	n/a	n/a	21/27 (78%)

**Tab. 4** Recommended diagnostic and therapeutic management of patients with heparin-induced skin lesions. The proposed diagnostic algorithm allows to point towards either one of the diagnosis. However, validation by appropriate laboratory tests is mandatory.

heparin-induced skin lesion	diagnosis	history	<ul style="list-style-type: none"> <li>itching</li> <li>no itching</li> </ul>	→HIHS →HIT
		clinic	<ul style="list-style-type: none"> <li>erythema, scaling, papules</li> <li>erythema, necrosis</li> </ul>	→HIHS →HIT
		biopsy	<ul style="list-style-type: none"> <li>dermal lymphocyte infiltrate</li> <li>occlusion of vessels</li> <li>other findings</li> </ul>	→HIHS →HIT →rare causes
		allergy testing	<ul style="list-style-type: none"> <li>HIHS</li> <li>HIT</li> </ul>	→testing alternative anticoagulants <sup>1</sup> →contraindicated
	therapy	continuous anti-coagulation required?	→yes	→change to save (HIT or HIHS) alternative <sup>2</sup>
→no			→discontinue anticoagulant treatment	

<sup>1</sup>In our opinion, allergy testing should be restricted to s. c. provocation tests and intend to find a suitable alternative anticoagulant.

<sup>2</sup>If HIT is not excluded, fondaparinux (off label use), dabigatran (off label use), rivaroxaban (off label use), argatroban or lepirudin can be used. If HIT is excluded, i. v. heparin is a safe option (15).

The low sensitivity of allergologic testing may be explained by the application route: It is well known, that patients with HIHS tolerate i. v. application (7). Therefore, it is tempting to speculate, that local effects in the subcutaneous tissue contribute to the allergic potential of heparins. In patients sensitized to several (and most likely similar) epitopes from different heparin preparations, this low sensitivity may be overcome. However, these assumptions have not yet been experimentally addressed. In addition to the low sensitivity, timing reduces the relevance of skin tests for the clinical decision making: At the earliest, it can be performed six weeks after lesions have cleared, and it is contraindicated in patients with suspected HIT. Hence, results from allergologic testing are not available when therapeutic decisions have to be made.

We propose histology to diagnose HIHS and to differentiate between the various causes of heparin-induced skin lesions.

Results from histology are usually available 1–2 days after performing the biopsy. Furthermore, histology allows differentiating between the causes of heparin-induced skin lesions. One major disadvantage of

histology is reliance on the experience of the pathologist (24). In addition, histology only allows diagnosing the representative lesion, which was biopsied. Yet, these limitations do not substantiate to refrain from performing a punch biopsy. However, presence of perivascular infiltration, which was frequently observed in our patient cohort, is not specific for HIHS. Hence, diagnosis of HIHS has to be based on the patient's history, the clinical presentation and results from histology.

Recently, a lymphocyte proliferation assay for a variety of heparin preparations has been described (10). Lymphocyte proliferation from 6 patients was in accordance with the clinical observations and allergologic testing in the tested patient population. If, these results can be reproduced in a larger cohort of patients; analysis of lymphocyte proliferation may become a valid diagnostic tool for the diagnosis of HIHS, even though this technique is not commonly available for routine diagnostics.

## Conclusion

Based on these observations, considerations and taking the lack of negative con-

trols into account, we propose the following procedure in a patient with heparin-induced skin lesions (▶ Tab. 4):

1. If continued anticoagulation is required, it should be changed to fondaparinux; which has a low cross-reactivity with heparin-preparations regarding HIHS (13, 16), and seems to carry an extremely low risk -if at all- to induce HIT and has even been described to successfully treat acute HIT (5, 17). Alternatively, anticoagulants chemically different from heparin; e. g. oral direct thrombin inhibitor dabigatran (off label use), the oral direct factor Xa inhibitor rivaroxaban (off label use), i. v. argatroban or hirudin, may be also used. All of which are not known to induce neither HIHS, nor HIT (11).
2. The cause of heparin-induced skin lesions should be identified by obtaining a detailed history, detailed clinical examination and a punch biopsy. If available, we also recommend performing the lymphocyte proliferation assay (10), which may help to identify possible cross-reactivity.

Given, HIHS is diagnosed by history, clinical presentation and histology; allergologic testing should not be performed for several reasons.

1. Having changed the anticoagulant therapy after diagnosis of heparin-induced skin lesions, the patients have already been “challenged” with a suitable alternative anticoagulant.
2. Allergologic testing is time and resource consuming.
3. With the exception of s. c. provocation, the sensitivity is too low.
4. HIT must be excluded.
5. Last, but not least, it puts the patients at risk to develop skin lesions and possibly introduces novel allergens.

Therefore, the only allergology testing which appears to be useful in this context is s. c. provocation used to define potential alternatives tolerated by patients with established HIHS rather than as diagnostic tool.

## References

- Alban S. From heparins to factor Xa inhibitors and beyond. *Eur J Clin Invest* 2005; 35 (Suppl 1): 12–20.
- Neykova A, Tzvetkov B, Merah AK, Matheron C, Kirsch M. The HIT treatment in a cardiac surgery patient. *Int J Cardiol* 2009; doi: 10.1016/j.ijcard.2009.03.027
- Berkun Y, Haviv YS, Schwartz LB, Shalit M. Heparin-induced recurrent anaphylaxis. *Clin Exp Allergy* 2004; 34: 1916–1918.
- Bircher AJ, Harr T, Hohenstein L, Tsakiris DA. Hypersensitivity reactions to anticoagulant drugs: diagnosis and management options. *Allergy* 2006; 61: 1432–1440.
- Efird LE, Kockler DR. Fondaparinux for thromboembolic treatment and prophylaxis of heparin-induced thrombocytopenia. *Ann Pharmacother* 2006; 40: 1383–1387.
- Eichler P, Budde U, Haas S, Kroll H, Loreth RM, Meyer O et al. First workshop for detection of heparin-induced antibodies: validation of the heparin-induced platelet-activation test (HIPA) in comparison with a PF4/heparin ELISA. *Thromb Haemost* 1999; 81: 625–629.
- Gaigl Z, Pfeuffer P, Raith P, Brocker EB, Trautmann A. Tolerance to intravenous heparin in patients with delayed-type hypersensitivity to heparins: a prospective study. *Br J Haematol* 2005; 128: 389–392.
- Grassegger A, Fritsch P, Reider N. Delayed-type hypersensitivity and cross-reactivity to heparins and danaparoid: a prospective study. *Dermatol Surg* 2001; 27: 47–52.
- Komericki P, Grims RH, Kränke B, Aberer W. Acute generalized exanthematous pustulosis from dalteparin. *J Am Acad Dermatol* 2007; 57: 718–721.
- Lopez S, Torres MJ, Rodriguez-Pena R, Blanca-Lopez N, Fernandez TD, Antunez C et al. Lymphocyte proliferation response in patients with delayed hypersensitivity reactions to heparins. *Br J Dermatol* 2009; 160: 259–265.
- Ludwig RJ, Schindewolf M, Utikal J, Lindhoff-Last E, Boehncke WH. Management of cutaneous type IV hypersensitivity reactions induced by heparin. *Thromb Haemost* 2006; 96: 611–617.
- Ludwig RJ, Schindewolf M, Alban S, Kaufmann R, Lindhoff-Last E, Boehncke WH. Molecular weight determines the frequency of delayed type hypersensitivity reactions to heparin and synthetic oligosaccharides. *Thromb Haemost* 2005; 94: 1265–1269.
- Ludwig RJ, Schindewolf M, Lindhoff-Last E, Boehncke WH. The influence of heparin's molecular weight and the incidence of delayed type hypersensitivity reactions revisited; in response to Grims et al. *Br J Dermatol* 2008; 158: 849–851
- O'Meara AC, Demarmels BF, Heizmann M. Fondaparinux as an alternative therapy in heparin-induced delayed-type hypersensitivity skin lesions. *Thromb Haemost* 2007; 98: 1389–1391.
- Schindewolf M, Schwane S, Wolter M, Kroll H, Kaufmann R, Boehncke WH et al. Incidence and causes of heparin-induced skin lesions. *Can Med Assoc J* 2009; 181: 477–481.
- Schindewolf M, Ludwig RJ, Wolter M, Himsel A, Zgouras D, Kaufmann R et al. Tolerance of fondaparinux in patients with generalized contact dermatitis to heparin. *J Eur Acad Dermatol Venereol* 2008; 22: 378–80.
- Schindewolf M, Luxembourg B, Lindhoff-Last E. Use of fondaparinux in patients with heparin-induced thrombocytopenia type II. *Vasa* 2006; 35 (Suppl 69): 70.
- Schindewolf M, Kahle B, Lindhoff-Last E, Ludwig RJ. Heparin-induced skin lesions: More common than suspected. *Phlebologie* 2010; 39: 5–11.
- Schindewolf M, Kroll H, Ackermann H, Garbaraviciene J, Kaufmann R, Boehncke WH, Ludwig RJ, Lindhoff-Last E. Heparin-induced non-necrotizing skin lesions: rarely associated with heparin-induced thrombocytopenia. *J Thromb Haemost* 2010; doi 10.1111/j.1538-7836.2010.03795.x.
- Singh S, Verma M, Bahekar A, Agrawal P, Duggal J, Ilescu M, et al. Enoxaparin-induced skin necrosis: a fatal outcome. *Am J Ther* 2007; 14: 408–410.
- Uncu H. A comparison of low-molecular-weight heparin and combined therapy of low-molecular-weight heparin with an anti-inflammatory agent in the treatment of superficial vein thrombosis. *Phlebologie* 2009; 24: 56–60.
- Utikal J, Peitsch WK, Booken D, Velten F, Dempfle CE, Goerdts S et al. Hypersensitivity to the pentasaccharide fondaparinux in patients with delayed-type heparin allergy. *Thromb Haemost* 2005; 94: 895–896.
- Warkentin TE, Roberts RS, Hirsh J, Kelton JG. Heparin-induced skin lesions and other unusual sequelae of the heparin-induced thrombocytopenia syndrome: a nested cohort study. *Chest* 2005; 127: 1857–1861.
- Whitehead ME, Fitzwater JE, Lindley SK, Kern SB, Ulirsch RC, Winecoff WE, III. Quality assurance of histopathologic diagnoses: a prospective audit of three thousand cases. *Am J Clin Pathol* 1984; 81: 487–491.